

Master in Clinical Dentistry (Oral Surgery)

Student ID Number: ORAL
1065514

POST-OPERATIVE COMPLICATION
AFTER CORONECTOMY OF MANDIBULAR THIRD
MOLARS

Table of Contents

CHAPTER I: INTRODUCTION.....	4
1.1 Background	4
1.2 Statement of the problem	5
1.3 Aims and objectives	6
1.4 Research questions	6
1.5 Scope and significance of the study	7
1.6 Chapterisation.....	7
CHAPTER II: LITERATURE REVIEW	9
2.1 Introduction	9
2.2 Flap design	10
2.3 Coronectomy with modern outlook.....	11
2.4 Imaging.....	14
2.5 Selection of the patient and informed consent	15
2.6 The procedure of coronectomy	16
2.7 The management in the postoperative period	18
2.8 Managing the Complexities	18
2.8.1 Complications arising in the intraoperative and immediate postoperative period ..	18
2.8.2 Late Complications.....	19
2.9 Research Gap.....	23
CHAPTER III: RESEARCH METHODOLOGY	24
3.1 Search Strategy.....	25
3.1.1 Inclusion Criteria	25
3.1.2 Exclusion Criteria	25
3.1.3 PICO Approach	26
3.2 Study Design	26
3.3 Data Collection.....	27

3.4 Critical Appraisal Skills Programme (CASP) Assessment of included studies.....	27
3.5 Summary	29
CHAPTER IV: RESULTS.....	30
4.1 Introduction	30
4.2 Description of the studies	35
4.3 Outcomes of Coronectomy of Wisdom tooth	41
4.4 Rate of failure and success of Coronectomy	42
4.5 Coronectomy as an alternative for MTM.....	43
4.6 Summary	44
CHAPTER V – DISCUSSION AND CONCLUSION	45
5.1 Introduction	45
5.2 Summary of findings.....	46
5.3 Strengths and limitations of the study	48
5.4 Conclusion.....	48
Reference.....	49

SAMPLE WORK

CHAPTER I: INTRODUCTION

1.1 Background

Coronectomy is a procedure in dentistry in which the third molars are extracted. However, there is a probability that the eruption of third molars may occur. They may be partially or totally impacted. Also, there are many problems and complications associated with the removal of third molars.

Per Moreno-Vicente *et al.* (2015), investigation of five cases did not specify any complexities that surfaced because of paraesthesia. This particular research more importantly stressed on the success of coronectomy. The conclusions drawn from this research bear a similarity on the randomized controlled trials conducted clinically by Renton *et al.* (2005), who investigated the incidence of IAN as a result of removal of lower third molars and coronectomy. A random procedure was done in which 128 patients required lower third molar surgeries and did undergo coronectomy, in this research done by Renton *et al.* (2005). About 102 teeth were removed in total in which coronectomy was done on 94 teeth. There was no nerve damage reported following the coronectomy in any of the cases; however, 19 patients who had extraction had nerve damage.

A research by Sencimen *et al.* (2010) did not rely on coronectomy in which rather than leaving the root as such with core pulp yet in the bone, the researchers conducted their research to explore the coronectomy if it warranted the need for a root canal. About 10 patients were categorized into 2 groups, who were having 16 mandibular third molars and had IAN in proximity. In one group, patient underwent coronectomy with endodontic treatment, but in other group – control group, the patients underwent coronectomy without any endodontic treatment. In the study, 8 patients who belonged to study group were infected as a result of extended flap opening; however, those who belonged to control group did not have infection. Of note, a research by Martin *et al.* (2015) concluded that the complications after coronectomy could be less than 10%.

In a study done by Renton *et al.* (2005), postoperative complexities after coronectomy are at 38.8%. The transitory IAN injury (t-IANI) was 8%, which was very low. t-IANI was 9.5% per Patel *et al.* (2013b) whereas the permanent IAN injury (p-IANI) was 4.8% according to Dolanmaz *et al.* (2009) and Patel *et al.* (2013b). The downside of these studies

was if the incidence of t-IANI or p-IANI after coronectomy is a failure or success and consequence of a complete extraction. The quality score of these studies is low and they are not relevant. Per the research done by Pogrel *et al.* (2004), the probability for Lingual Nerve Injury (LNI) is rare and is at 2% for t-LNI, which is also a score of low quality.

The research of Leung and Cheung (2009) throws light on the negative impacts of coronectomy seriously taken into account by clinicians. In this study, in about 10% to 20% of the cases, the patient felt pain after coronectomy, which raised and reached 41.9%. This study had a large sample size and good quality score. Monaco *et al.* (2012) observed that swelling after coronectomy was rare and was at only 4.6% of the cases. In a research of Renton *et al.* (2005), the medium / high quality score got by the study highlighted that a small number of patients had dry socket infections (DSI) after coronectomy. About 12% of the patients had this problem in accordance with their study. Patel *et al.* (2013b) voiced that immediate infection after coronectomy can happen but occasional. If the primary closure and antibiotics were involved, the chance is higher; however, the percentage obtained in this study is only 9.5% and it is a low-quality study. Patel *et al.* (2014) said that while coronectomy is conducted, the pulp chamber is getting decompressed, which gives the space for pulpal oedema. Due to the coronal bone that is being formed, the scope for migration of the root is less per O’Riordan (2004) and so is the chance for infection (Kohara *et al.*, 2015).

The success after coronectomy procedure affirms the necessity for the adoption of the suitable method by the surgeon in addition to the patient selection, according to Jerjes *et al.* (2010) and Bataineh (2001). The surgeon’s expertise plays the role in avoidance of permanent IAN sensory dysfunction. If the surgeon has the training and expertise of less than 10 years, the patients have high degree of risk for postoperative complexities after coronectomy (Monaco *et al.*, 2015).

1.2 Statement of the problem

The vital teeth and their damaged fragments will heal on their own. While removing an uninfected tooth, the root broken will be left to heal itself to heal by itself (Knutsson *et al.*, 1989; Fareed *et al.*, 1989). This forms the basis of coronectomy. But all the third molars cannot be extracted by coronectomy. The infected teeth are not suitable to be extracted by coronectomy, as they may aggravate the situation. The horizontal impaction of the tooth also

may pose the problem, as it may lead to IAN injury (Pogrel *et al.*, 2004). Hence, decision has to be made shrewdly pertaining the situation and selection of the case.

Many postoperative problems may arise either long-term or short-term. According to Renton *et al.* (2005), some patients felt pain post coronectomy and the percentage is low. Contrarily, study of Hatano *et al.* (2009) recorded high occurrence of postoperative pain after coronectomy. In addition, incidence of dry socket was also reported in certain cases rather than complete extraction of third molar. This was closely related to reduction of the exposed bone amount and the effect of stabilisation of clots in the primary closure which is needed for the coronectomy. But, certain authors state that coronectomy decreased the occurrence of nerve injury and there were no sensory damages (Leung & Cheung, 2009; Hatano *et al.*, 2009; Renton *et al.*, 2005). Therefore, it cannot be easily concluded that coronectomy is the decisive answer to the removal of lower third molar because certain problems are surfacing postoperatively. Hence, this becomes the basis for this current research.

1.3 Aims and objectives

This study will assess the postoperative complications of coronectomy procedure done on the mandibular third molar (MTM). In line of this aim, the below objectives are considered and framed:

- a) To assess the outcomes of coronectomy of the wisdom tooth in terms of complications such as permanent or temporary failure of the IAN, the rate of infection and other morbidities.
- b) To examine whether coronectomy is a viable alternative for the extraction of the MTM.
- c) To evaluate the rate of failure and success of coronectomy as a surgical procedure for the extraction of MTM.

1.4 Research questions

It is believed by the researcher that there is a necessity to investigate if there may be any postoperative complications after coronectomy of mandibular third molar. Hence, the below research questions are framed:

- a) What are the outcomes of coronectomy of the wisdom tooth in terms of complications such as permanent or temporary failure of the IAN, the rate of infection and other morbidities?
- b) Is coronectomy a viable alternative to traditional MTM extraction procedures?
- c) What is the rate of failure and success of coronectomy as a surgical procedure for the extraction of mandibular third molar?

1.5 Scope and significance of the study

This research is carried out to identify the scope for any postoperative complications after coronectomy done on the wisdom tooth. The researcher has found that postoperative complications following a coronectomy procedure of the third molar would include incidence of nerve transection that happens because of the application of rotary instruments that are used deep in the socket or could arise because of the extraction of a root that has been punctured by a nerve (Gulicher & Gerlach, 2001). The injuries that are listed above can cause the patients to have paraesthesia, dysesthesia, and anaesthesia in particular to the buccal gingivae, chin, and the lower lip. Other parameters that cause complications after coronectomy are deep impaction, advancing age, unerupted tooth, and exposure to IAN that is intraoperative and certain specific radiographic indications could pose risks after a coronectomy (Knutsson *et al.*, 1989).

With regard to this study, the researcher expects the same type of issues, as they have been explained by the other authors previously. However, the researcher also expects to identify variations in the kind of complications that existed after coronectomy in the past and in the present day. This study also wants to identify whether coronectomy is the only possible option for the extraction of mandibular third molar. This study would also adopt the two methods - sectioning and orthodontic extrusion and compare them with the coronectomy procedure to recognise the possibility of coronectomy with the other methods. This study also intends to determine the scope for failure and success in the coronectomy procedure as an option in the extraction of mandibular third molar.

1.6 Chapterisation

The current research has the below chapter scheme mentioned as below -

Chapter I- The first chapter of the current study is the Introduction wherein elaborate information about the research topic is covered. Moreover, the statement of the problem, the aim and objectives of the research and the scope and significance of research are elucidated.

Chapter II- The second chapter is the Literature Review wherein previous researches in the context related to the current research are explored and discussed. In this section, a detailed elaboration about the flap design, coronectomy with modern outlook, imaging, selection of the patient and informed consent, procedure of coronectomy, management in the postoperative period, complications in the intraoperative and immediate postoperative period, late complications, and research gap is given.

Chapter III- The third chapter covers the Research Methodology section. This section explains the type of research methodology adopted in the current research which deals with postoperative complications of coronectomy on lower third molar.

Chapter IV- The fourth chapter covers the results section. The results of the current study are covered and an analysis pertaining to the efficiency of coronectomy as an option for extraction of mandibular third molar is undertaken.

Chapter V- The fifth chapter is the discussion and conclusion section wherein the results of the current research are examined so as to analyse the coronectomy complications in the postoperative period. Furthermore, the conclusions of the study are drawn and recommendations for future researches are revealed.

CHAPTER II: LITERATURE REVIEW

2.1 Introduction

According to the American Dental Association, the technique that is utilised to remove a tooth which has not yet broken through the gum surface; however, has a potential of damaging the nerve that gives the sensation to the lower chin and lip is called the prejudiced odontectomy or coronectomy. In this method, the adjacent gingiva is left off from the mandibular third molar tooth and the crown of the tooth is sectioned off the root. On account of the extraction of mandibular third molar that is impacted, the patient may have an inferior alveolar nerve injury. For these patients, coronectomy is the solution. By means of coronectomy, the patients have the decreased risk of nerve injury. Because of this method, the other postoperative complications like pain, brief loss of sensation, and swelling that are associated with the extraction of impacted mandibular third molar tooth can be avoided. The significance of this technique is that the area that was occupied by the root of the tooth is closed by the mandibular bone in that area. In order to avoid damaging the nerve that provides sensation ability to the lower chin and lip, the mandibular third molar tooth roots are left intact.

In the case of the patients who have the high risk of lower third molar teeth, this method lowers the possibility of injury of the nerve. When the mandibular third molar tooth nerves are sighted beside the inferior alveolar nerve canal on the dental diagnostic imaging, this method is undertaken and the roots are left as they are. In 1989, Knutsson *et al* proposed this method; however, this method exposed the root and this procedure contributed to the infection (Knutsson *et al.*, 1989). In fact, coronectomy is relatively a new technique in the field of dentistry. Hence, the number of publications related to the coronectomy is only a few for the purpose of evaluating its efficiency as a therapeutic option. In dentistry, the inferior alveolar nerve injury is very prominent while removing the impacted lower third molar tooth or wisdom tooth. The injury of IAN after the operation for the impacted lower third molar teeth was 0.4% to 0.8% over time. During the dental procedures, the pressure can be exerted by the roots while removing the tooth, elevation can be done vigorously by the elevators. When these happen, the injury to the inferior alveolar nerve can happen. Conventional panoramic x-ray is taken to evaluate, when the inferior alveolar nerve is near the impacted lower third molar. The buccal, lingual, mylohyoid, and inferior alveolar nerves will be near

the impacted mandibular third molar teeth (Loescher et al., 2003). The buccal approach is used along with the traditional bur method succeeded by the extraction of buccal bone by means of a fissure bur down to the level of crown root junction in this procedure. The first and second molar teeth are not in close proximity to the inferior alveolar nerve, but it is only the third mandibular molar that bears the impact. Therefore, this method is suggested as a deliberate method of tooth root retention in which the crown of the impacted lower third molar tooth is separated and root is left because it may be proximally related with the IAN and this root is not touched in order for the nerve remains uninjured (Ahmed et al., 2011).

A major procedure should be undertaken for the bone to proceed with the sectioning of the crown of the tooth in the buccolingual and mesiodistal directions, when the lower third molar is in the horizontal direction. The aesthetics for the complete extraction of the lower third molar is associated with the crown part of the tooth in this case. The tooth root will need to be removed while sectioning of the crown in root mobilization, as the mobilization of wisdom tooth may predispose to the morbidity of alveolus. The eruption of the root fragments in the mouth may be affected by the root migration. The late migration of the root fragment may happen in certain cases in the future; however, it is unpredictable. The removal is not that difficult, since in these cases there is no nearby inferior alveolar nerve and the roots of the tooth are mobile. But, root fragments mobilize to the secured position with regard to the inferior alveolar nerve in this circumstance and if the extraction of the root is necessary, then the inferior alveolar nerve would not be injured later (Pogrel et al., 2004). In order for the root fragments to erupt further, it takes a decade as per the case reports (Drage & Renton, 2002).

2.2 Flap design

If a tooth is impacted partially, a triangular flap with a mesial releasing incision distal to the second molar is performed to get the primary closure of the wound. During these situations, the releasing incision will not be replaced and to obtain closure, the flap is sewed to the lingual side. It is not difficult to get a primary wound closure in the cases of completely impacted lower third molar, as there is enough amount of gingiva and the dental surgeon has a choice of envelope or triangular flap with the help of modified wards incision. But there are some disadvantages of this operation, which include deep periodontal pockets on the distal side of the second molar tooth in relation to those after removal, root migration which may require a second procedure, post-procedural infection locally, dry tooth socket, unintentional

root removal, post-procedural pain that will raise the danger of inferior alveolar nerve injury and additional enclosure because of failed coronectomy (Renton et al., 2005; O’Riordan, 2004; Tolstunov et al., 2011).

- The below conditions inhibit the mandibular third molar extraction by means of coronectomy (Bonetti et al., 2008).
- The inferior alveolar nerve canal is not met by impacted lower third molar tooth roots.
- Inferior alveolar nerve is affected by the anaesthesia already.
- The root apex or crown infection is present on the lower third molar tooth.
- The tooth is mobile at present and this may constrain the procedure of coronectomy, since this tooth may be the origin of migration or infection.
- Systemic diseases like AIDS, diabetes mellitus, chemotherapy, and the regional conditions like metabolic bone diseases like fibrous dysplasia and past medical history of radiotherapy to the jaw.
- The horizontal impaction of the mandibular third molar may interfere with the inferior alveolar nerve and hence the coronectomy of the lower third molar may affect the inferior alveolar nerve.

2.3 Coronectomy with modern outlook

There are two types of coronectomy (Rood & Shehab, 1990):

1. Modified coronectomy.
2. Grafted coronectomy.

The modified grafted coronectomy needs the crown and parts of the roots of an impacted lower third molar in the circumstances where there is a high risk of inferior alveolar nerve injury. The intraoperative root loosening can be limited by the modified coronectomy method. At the time of extraction and the sectioning off the crown, the radicular remnant is preserved and thereby the injury to the inferior alveolus nerve is averted. In order to decrease the chance of periodontal pockets on the distal second molar, as a modification, this method encourages the production of periodontal scaffolding. This can be done by means of grafting and hence the name modified and grafted coronectomy (Leizerovitz & Leizerovitz, 2013).

Coronectomy is the ideal choice for those with the risk for inferior alveolar nerve injury; however, this approach is sensitive and has difficulties. This procedure targets only the crown of the impacted lower third molar and the roots of the tooth are kept intact intentionally in order to avoid any inferior alveolar nerve injury, either direct or indirect. As a retrospective study of 33 patients, this approach was first proposed by Knutsson *et al* in 1989. There were about 6 more papers on the coronectomy that contain 2 retrospective researches, 3 case reports, 1 randomized control tribulation by Renton *et al* in the year 2005. About 128 patients were randomly selected and they did undergo either coronectomy or extraction of wisdom teeth (Pogrel, 2009a; Dolanmaz et al., 2009). The patients who did undergo the extraction were predisposed to having the inferior alveolar nerve deficit after the operation rather than those who underwent the coronectomy. Apart from the IAN injury possibility, no other surgical outcome could be elicited. All other researches gave the associated inferences. One of the findings of the study, after coronectomy, was slow displacement of the wisdom tooth root. If the root is exposed intraorally, then the root will be abstracted, but the danger of damage to the IAN in the next surgery is decreased as the root has moved away from the IAN.

In the evaluation done by Pogrel *et al.* (2004) of 41 patients, who had coronectomy of 50 mandibular third molar teeth and the follow-up for a minimum of 6 months, this coronectomy was employed because the diagnostic radiographs suggested there was close proximity between the inferior alveolar nerve and the roots of the teeth. There were no inferior alveolar nerve damages reported in the study as per the researchers.

At the Prince Philip Dental Hospital, a prospective study of 4338 lower third molar surgeries between the years 1998 and 2005. This study has been regarded as the biggest study in the history of dentistry done by Leung and Cheung (2012). The incidence of linguistic nerve injury was 0.69% and the percentage of inferior dental nerve injury was 0.35% (Leung & Cheung, 2009; Cilasun et al., 2011; Dodson et al., 2012).

In another research conducted by Monaco *et al.* (2012) in which 43 coronectomies of impacted lower third molars in 20 women and 17 men (totally 37 patients) were examined for the postoperative complications, the inference was got that the coronectomy is the safe option rather than the full removal in the circumstances when the third molar is near the mandibular canal. The migration of the tooth root is asymptomatic commonly; however, if the patient is to undergo a second operation, the risk of IAN injury is less. These researchers utilised cone-

beam computed tomography (CBCT) to ensure that IAN was near the teeth that needed coronectomy (Lieblich et al., 2012; Dodson et al., 2012; Monaco et al., 2012; Chin Quee et al., 1985).

Several researches indicated the occurrence of inferior dental nerve injury while removing the third molars and these researches mention that after 4% to 5% of the surgeries, the inferior alveolar nerve injury happens 1.3-7.8%) (Sedaghatfar et al., 2005).

The failure of the coronectomies attributes to the most complicated issue of inferior alveolar nerve injury in which the remaining root was unintentionally moved. This necessitated the dentists to remove the root completely in 4% to 38% of the cases (Freedman, 1997; Dolanmaz et al., 2009). The obvious merit of this procedure is averting the inferior alveolar nerve injury. This procedure is not without any demerit. Formation of deep periodontal pockets on the distal aspect of the second molars similar to those after the removal, dry sockets, migration of the root that requires a second surgery, postoperative pain, post-procedural infections locally, unintentional root extraction during the operation thereby raising the risk of inferior alveolar nerve injury (called as failed coronectomy) (Pogrel et al., 2004; Drage & Renton, 2002; Chin Quee et al., 1985) are the disadvantages.

According to the research done by Rood and Shehab in 1990, darkening of the root, diversion of the canal, and interruption of white line of IAN are related to inferior alveolar nerve injury. The researchers Sedaghatfar *et al.* (2005) in 2005 have done retrospective cohort study and they confirmed that narrowing of the root is an added important sign to determine the nearness of the nerve and tooth root. The radiographic signs are indicative of high degree of risks of nerve injury related to the extraction of corresponding third molar teeth, but not related to prevention of injury, when the tooth is extracted. The solution for the extraction of symptomatic lower third molar and those who have the risk of having inferior alveolar nerve injury in the radiography is the coronectomy as an alternative for the patient. On account of the complications in the procedure and the variations that may come up in the radiographs, it is customary that a qualified surgeon should do the operation.

The researchers Hatano *et al.* (2009) did a comparative study of coronectomy and conventional extraction on a population of 220 patients. The researchers divided them as 102 in the coronectomy and 118 in the convention removal groups. The coronectomy group had a mean follow-up of 13.5 months and 13 months in the conventional extraction group. There

were about six inferior alveolar nerve injuries, which accounted for 5% of the cases in the conventional extraction group and there was a report of 1 patient who had nerve injury and accounted for 1% of the case. The danger of such an event is demonstrated in the radiographs taken as part of the treatment modality. Researches have demonstrated that on dental radiographic evidence, darkening and/or root interruption of the white lines of the canal, diversion of the inferior dental canal, constriction of the canal, and deflection of the tooth root represented a probable nerve proximity to the tooth (Howe & Poynton, 1960).

The procedure of coronectomy of the teeth that are not erupted related to the dentigerous cysts is the solution, if there is a high possibility of inferior alveolar nerve injury or the possibility of mandibular fracture, per (Patel et al., 2013c). More researches with large numbers and long follow-up are needed to identify long-run result of the electively retained root.

2.4 Imaging

The diagnostic tool used for the patient screening is the panoramic radiograph, which is utilised as the standard imaging tool. When a more detailed imaging technique is needed, CBCT is recommended (Gomes et al., 2008). However, it is controversial when it comes to the specificity and sensitivity of the panoramic dental radiograph in order to find the IAN damage. The range for specificity is 30% to 98% and the range for sensitivity is 24% to 66% (Gomes et al., 2008; Susarla & Dodson, 2007). CBCT is the preferred imaging choice for the patients with high risk. When CBCT is compared to the panoramic radiograph in regards of nearness of the IAN to the impacted lower molar teeth, the specificity and sensitivity are 93% and 77% for CBCT and 70% and 63% for panoramic radiographs (Tantanapornkul et al., 2007). In order to assess impacted tooth for tooth location, actual size, and tooth relations to other anatomies like IAN and lingual plate of the mandible in three dimensions CBCT is the perfect choice, as found in recent literatures. But the radiation exposure is equivalent to or slightly higher than conventional imaging. Economic consideration and advantage versus disadvantage must be estimated (Kapila et al., 2011).

The panoramic radiograph criteria for the low dose cone beam CT (LD-CBCT) have been identified by the researchers so as to have suitable use of lower molar operation (Frafjord & Renton, 2010).

They are as the following:

1. Darkening of the roots.
2. Diversion of the inferior alveolar canal.
3. Narrowing of the canal.
4. Interruption of the white line of the canal.
5. Juxta apica area.
6. Deflection of the roots.

The radiolucent area that is well-circumscribed and lateral to the root rather than the apex is the juxta apical area. The MRI and CT studies identify that this is a continuation of the IAN lamella with periodontal lamina dura of the neighbouring tooth (Renton, 2011). The positive postoperative IAN deficit indicators were darkening of the root or the presence of two or more radiographic signs (Leung & Cheung, 2011). Gaeminia *et al.* assessed the risk for IAN injury, which ensured that CBCT could assess the risk at an optimal level and that surgical planning can be done effectively when compared with panoramic diagnosis (Ghaeminia et al., 2011). A latest research done by Renton, *et al.* found another category of patients, who may get the advantage of the preoperative CBCT assessment and coronectomy. These patients will have an absence of lingual plate and inferior dental nerve will sit in between the mucosa and the lingual aspect of the tooth (Renton, 2011). The suitable surgical approach can be identified from the CBCT approach. The coronectomy group patients who have pathology and who do not really need a coronectomy can be found from the CBCT. If the teeth have osseous pathology, the removal of the teeth will bring in treatment-related injury to the inferior alveolar nerve.

2.5 Selection of the patient and informed consent

The presence of mobile or non-vital teeth, active infection, and cyst associated with teeth, and teeth with incomplete root formation play the prominent role in the patient selection for the procedure. The teeth with dentigerous cysts can also be treated with the coronectomy operation in accordance with the recent reports (Patel et al., 2013c). The patients who have been about to undergo radiation therapy or immune compromised patients cannot undergo the coronectomy procedure (Pogrel, 2007; Gady & Fletcher, 2013; Cilasun et al., 2011). However, age is not the factor. Coronectomy can be undertaken for the patients who are well above 40 years for the lower third molar teeth with the highly probable inferior

alveolar nerve injury (Monaco et al., 2012). The informed consent also plays the major role in the procedure. While getting the informed consent from the patient, the reason for undertaking the procedure, potential postoperative complications, potential intra-operative complications, possible second stage intervention, and suitable management of the complications should also be elaborated (Renton, 2012). CBCT can be used as a medium for the comprehension of the rationale behind this procedure.

2.6 The procedure of coronectomy

Extensive pre-procedural preparation is required for the coronectomy with respect to the surgeon, patient, and assistants. The learning curve for the procedure is very long and it must not be taken as a less invasive third molar removal, instead it is a new method of surgical technique with the requirement of extensive technical indications and demands. The procedure of traditional odontectomy for the lower third molar removal and the surgical method of coronectomy bear some resemblances. The steps involved in the procedure include meticulous method, precision with the completion of partial odontectomy with less force, and necessary exposure of the third molar. However, there is no agreement on providing preoperative or postoperative antibiotics following the procedure of coronectomy (AAOMS, 2017). For partially impacted third molar with an indicative coronectomy, the postoperative antibiotics are prescribed commonly. The latest researches have not proved the probable infection arising from the remnant of the root due to the pulp necrosis (Dolanmaz et al., 2009). The endodontic treatment will not avoid the infection and hence this treatment is not needed as part of the coronectomy (Sencimen et al., 2010). Under local anaesthesia or local anaesthesia IV sedation, the procedure of coronectomy can be done. The patient's compliance, comfort, and cooperation are needed for the successful coronectomy because of the precision needed for the operation. A traditional mucoperiosteal flap is reflected. A wide area needs to be exposed as an important step, since small amount of distal alveolar bone and enough buccal bone removal must be done. Up to 2 mm below the cement-enamel junction, the crown of the tooth needs to be exposed. Before carrying out the sectioning of the crown, full anatomical view of the crown of the third molar is needed. The result of the coronectomy needs to be enhanced because of the crown sectioning. The procedure will be carried out under loop magnification (x2.5) for the optimal accuracy and the precision of the method. By means of the fissure bur, the crown is sectioned using 45° bevel, starting 2 mm below the cemento-enamel junction through the pulpal activity until a thin layer of enamel is left

lingually. This is important for the safety of lingual nerve. The lingual nerve is in between the lingual mucosa and lingual enamel wall of the crown. The level of the odontectomy is below the lingual nerve as ensured by the 45° beveled sectioning of the crown and this decreases the chance of damage to the nerve. Less force is used to separate the roots from the crown. Inadvertent mobilization of the root or undesirable sectioning of the crown will take place and it will further complicate the procedure, when the cut is not made deep enough (Gleeson et al., 2012; Genu & Vasconcelos, 2008; Pogrel, 2009b). A bur can be utilised to eliminate the lingual enamel that can be attached to the root. The root surface must be below the buccal crest of the socket when the sectioning ends. When this cannot be completed, a further root surface reduction of 2 mm to 3 mm below the buccal crest is necessary.

The healing of the bone over the remnant of the root is eased with root reduction below the buccal crest of the socket (Pogrel et al., 2004). Multiple sectioning of the crown can be tried thereby removing the crown in two different pieces, if the sectioning of the crown is difficult because of the space constraints (Genu & Vasconcelos, 2008). T-sectioning can be utilised in this circumstance. The ablation of the exposed pulp and the spot welding at the orifices of the root canals with a diode contact fiberoptic laserprobe at a wavelength of 980 +/- 10 nm can be done, as a way of avoiding probable infection. The procedure requires the settings: 400 µm fiber, Power: 1.5 W CW, exposure time for spot welding: 5 seconds of radiation followed by 5 seconds of rest period (Schoop et al., 2006; Gutknecht et al., 2005). A small change in the temperature of the root that is less than the temperature for the safe exposure for the hard and soft tissues around the remnant of the root is ensured by the short exposure of the coronal part of the remnant of the root to the laser beam (Hmud et al., 2010; Alfredo et al., 2008; Liu, 2006; Odabaş et al., 2007; De Coster et al., 2013). Copious amounts of normal saline are utilised for the irrigation of the wound. The irrigation of the wound is a very important step in the care undertaken for the surgical wounds. In coronectomy procedure, the irrigation is done to the sockets with the use of normal saline. Before closing the wound, the tooth debris, the remnants of the pulp and bone are removed. Using 4-0 Vicryl Rapide®, the surgical wound is closed in a watertight fashion by means of interrupted vertical mattress sutures. This suture will give necessary isolation of the remnant of the root from the oral environment (Renton, 2013b).

2.7 The management in the postoperative period

In the postoperative period, chlorhexidine gluconate 0.12% oral rinse and analgesics must be prescribed. The importance of the subsequent follow-up visit and panoramic radiograph must be informed to the patient. In case of symptoms or root eruption, the patient may need to be re-evaluated.

In order to decrease the risk of infection, certain researchers utilise the antibiotics postoperatively (Hatano et al., 2009; Gady & Fletcher, 2013; Cilasun et al., 2011), while certain researchers think that, unless pericoronal infection is present, common antibiotic use is not needed. The antibiotic is administered only for the partial impaction of the third molar in which situation coronectomy is warranted. A detailed operative note holds all the important steps in the procedure. A letter stating the detailed information about the surgery, the rationale behind the surgery, follow-up, probable early and late complications inclusive of probable second-stage procedure that may be needed can be sent to the consulting dentist.

2.8 Managing the Complexities

2.8.1 Complications arising in the intraoperative and immediate postoperative period

Delayed and immediate failure of the operation can arise in the coronectomy in the form of mobilization of root segment, which is specific to the technique. A small amount of force can be used to achieve the crown-root separation after the sectioning to avoid the failure of the operation. Root remnant can become mobile if too much of force is used essentially if the patient has cone-shaped roots and this will mean the extraction of the root while doing the procedure and this will result in the failure of the coronectomy and possible inferior alveolar injury.

Fast migration of the root and eruption of the root will happen due to root mobilization in accordance with (Gady & Fletcher, 2013). Small conical roots that exist in female patients are affected by the mobilization and in order to prevent this complication from occurring extreme care is needed, in accordance with (Renton, 2012). But with respect to gender, root shape, age, depth of impaction and pattern, coronectomy failure cannot be associated with any significant risk factors according to (Leung & Cheung, 2009). The failure percentage for the coronectomy is going from 2.3% to 38.3% (Renton et al., 2005; Hatano et al., 2009; Renton, 2013b; Cilasun et al., 2011; Leung & Cheung, 2009; Long et al., 2012).

Dry socket is one of the complications that happen most commonly. Healing, need for root removal, and infection may happen because of the dry socket (Renton, 2012). The percentage of incidence of dry socket is from 10% to 12.1% (Renton et al., 2005; Patel et al., 2013a). This complication can be treated with the use of oral rinse chlorhexidine and utilising resorbable dressings. The healing can be delayed because of root mobilization, retention of enamel, wound dehiscence (Patel et al., 2013a). It is very important to separate the root remnant from the oral cavity. For the roots to be covered by the bone, the soft tissue must cover the roots and this fact was demonstrated by the experimental data from a research on submerged roots (Whitaker & Shankle, 1974).

There are conflicting data with regard to postoperative pain as felt by the patient. When the coronectomy and traditional extraction are compared, the patients who underwent coronectomy reported less pain than those who underwent traditional removal (Leung & Cheung, 2009, 2012). A small amount of bone was removed and this was the reason. According to one research, there was more postoperative pain in the control group (Hatano et al., 2009). The remnant of the root had to be extracted in case of prolonged intermittent pain. Since the root had mobilized away from the inferior alveolar nerve, the second stage of the procedure needed to be done cautiously (Monaco et al., 2012).

The percentage of incidence of infection after the coronectomy is from 0.98% to 5.2% (Renton et al., 2005; Whitaker & Shankle, 1974). Broad-spectrum antibiotics, socket irrigation, and anti-inflammatory medications can be used to treat this condition. No therapy would be required, when the infection gets resolved in a few days (Patel et al., 2013a). Otherwise, the roots need to be removed, if the infection of the patient is persistent and recurrent (Renton, 2012).

2.8.2 Late Complications

The migration of the tooth root is a late complication that may come as a consequence of coronectomy with incidence percentage from 13.2% to 85.29% (Leung & Cheung, 2009). In the first year of the surgery, upward root migration happens, essentially in the first 6 months and as the bone remodels, this migration will be finished in 2 to 3 years. According to the study conducted by the researchers Leung and Cheung, there was migration of the tooth root in more than half of the cases they encountered. They found that this had taken place in the first 3 months of the surgery and then diminished after 12 to 24 months. The mean

distance of the migration was 3.06 mm (Leung & Cheung, 2009). The same researchers found a migration of the root to a distance of 2.8 mm in a latest research they conducted, with a 3-year follow-up (Leung & Cheung, 2012). Between the 24th and 36th month, the migration of the root did not taken place barring four roots that erupted and removed. The females did have more distance of root migration than the males when analysed statistically, which is 3.4 mm for female patients and 2.4 mm for the male patient. According to Hatano *et al.* (2009) the root migration was found to be 85.3% in 102 coronectomies where the mean follow-up was 13.5 months. The movement of the root remnants went high in the first postoperative 6 months with a mean of 3.4 mm with a high migration rate of 85%, according to a study conducted by Sencimen *et al.* (2010). According to a report of Pogrel, nine roots erupted and they need to be removed and the root migration was 30% in 150 cases within a period of a year (Pogrel, 2009a). In a study, bone healing was completed in 12 months after the surgery for the retained root and the occurrence of the root migration was 4.1%. The root remnant did not need to be removed because of this asymptomatic migration. In a 3-year follow-up research done by Leung and Cheung, the cases reporting root eruption becoming symptomatic and causing an extraction of remnant were 3% (Leung & Cheung, 2012). The roots are usually extracted when they erupt or when they are causing the symptoms. The root remnant that mobilizes away from the inferior alveolar nerve canal can be removed safely in a delayed manner in an uncomplicated procedure using local anaesthesia. The root remnant erupted and entered the IAN canal, which is very peculiar (Drage & Renton, 2002). The root remnant has not been associated with pathology thus far. Moreover, no mandibular fracture of osteomyelitis has been reported with such surgeries. It is considered rare that nerve injury happens as a result of coronectomy. According to the researchers conducted by Renton *et al.* (2005) and Cilas *et al.* (2011) there was no reported IAN injury. The studies done by Leung and Cheung (2009) and Hatano *et al.* (2009) demonstrated an IA impairment of 1 out of 155 and 102 cases, respectively. While doing the traditional third molar operation, there is less likelihood of lingual nerve being injured; however, when such an injury occurs, there is more severe damage to the nerve. The lingual nerve (LN) is less likely to be injured in the coronectomy barring one transient impairment of lingual nerve due to lingual retraction, according to Pogrel (2009a). There is a report of asymptomatic apical radiolucency, which occurs in the apical part of the root that is migrating in the first three months in the radiograph (Geisler, 2013). This is a benign finding on this radiograph, but it may look like an apical pathology because of the delayed regeneration of the bone. Radiographically, two cases were analysed by O’Riordan with this finding and found that after coronectomy, apical

radiolucency was evident (O’Riordan, 2004). Around the apex of the remnant, the lamina dura was seen.

Nowadays the nerve damage can be avoided easily because of the advances in the imaging. In accordance with the research done by Renton, law cases are often filed for defective planning and assessment, unelaborate consent procedure, improper management of the patient after the nerve injury and avoidable nerve injury (Renton, 2013a). Temporary IAN involvement as a complication of the third molar surgery is 1% to 5 %, while permanent impact is from 0.04% to 25% (Zuniga, 2009). According to a self-report done by the oral surgeons, the temporary and permanent nerve injury was 4 in 1000 mandibular third molar removals for the inferior alveolar nerve injury and 1 in 1000 removals for the linguistic nerve. The incidence of permanent injury according to a self-report was 1 in 2500 mandibular third molar removals for IAN and 1 in 10000 mandibular third molar removals for the linguistic nerve injury (Robert et al., 2005). The occurrence of nerve injury is reported as 12% if the imaging risk parameters are present. According to Tay and Zuniga, the third molar surgery accounts for 52% of the most general IAN injury, which needs the intervention Tay and Zuniga (2007). The paraesthesia is the common symptom that most patients can present. The other symptoms are dysesthesia and allodynia, which are very problematic (Hillerup, 2007). The incidence of nerve injury was very high in the below 20-year-old group of patients and that the injury depends on the surgeon’s expertise (Bataineh, 2001). The extent of impaction and inexperience are related to nerve impairment in accordance with (Cheung et al., 2010). The parameters related to higher occurrence of IAN paresthesia include horizontal impactions, patients in 26 to 30-year age group, close proximity to IAN canal, root involvement, and surgeon’s expertise (Jerjes et al., 2010). There is a possible challenge of properly sectioning the horizontally impacted tooth without endangering the IAN. CBCT must be used to analyse these cases before the surgery. Horizontal impaction can be a contraindication for coronectomy according to (Gady & Fletcher, 2013). According to Pogrel, coronectomy is not suitable for these cases (Pogrel, 2009b). Hatano *et al* also found that horizontal impaction of third molar can challenge the crown sectioning, as they analysed in the series of cases (Hatano et al., 2009). The horizontal impaction of the molar is not always a hindrance for the coronectomy. But the technical aspect of the safe sectioning of the horizontally impacted molar may be difficult. Training and experience make up the expertise that a surgeon has. The coronectomy is relatively a new procedure in the oral surgery and hence a learning curve would be needed. The procedure of coronectomy is a technically

sensitive procedure (Geisler, 2013). In the therapy for exposed pulp which is treated using endodontic treatment, prevention of infection due to pulp necrosis is the reason for the utilisation of spot welding for the orifices of the root canals and diode laser for pulpotomy. The pulp ablation using the laser technique is done by the dentists around the world and this is a safe procedure. The orifices of the root canals are completely closed by the laser and dental pulp is isolated from the oral cavity (Liu, 2006). In a period of 12 months, there was no occurrence of infection or any other complexities in 24 cases of coronectomy done with laser ablation and that the exposed pulp does not need any treatment as per the evidence in the literature (Frafjord & Renton, 2010). According to a research conducted by Sencimen, *et al.* in which endodontically treated remnants of the root and untreated roots that were retained after the procedure of coronectomy, the method is not affected by the endodontic therapy (Sencimen *et al.*, 2010). The migration of the root is the important late sequela of the coronectomy procedure. The eruption of the root in the mouth is inhibited by keeping the occlusal surface of the tooth root 2 mm to 3 mm below the crest of the bone. The bone will form in this distance over the retained fragment of the root (Pogrel *et al.*, 2004). The submerged root fragments are vital and sustain coronal bridging in accordance with Whitaker, *et al.* The circumferential closure of the coronal rim of the pulp canal by means of calcified tissue with no inflammation is called the coronal bridging (Whitaker & Shankle, 1974). The retaining of the enamel fragment on the remnant of the root because of the procedural challenge is called enamel lipping. This happens in the disto-angular impacted third molar which is near the second molar in common. In the postoperative radiograph, the enamel lip can be spotted and this will endanger the long-run retention of the tooth root, since the enamel will act like a foreign body and this will not heal the dry socket (Patel *et al.*, 2013b). When the coronectomy group results are compared with control group of conventional extraction of the teeth, the outcomes favour avoidance of IAN damage (Patel *et al.*, 2013a). No IAN injury was reported in the coronectomy by Cilasun *et al.* as well as Renton *et al.* One case of IAN injury in the coronectomy which makes 0.06% by Leung and Cheung. According to Hatano *et al.* one case of temporary defect which makes up 1%. But the conventional extraction accounted for 8.3% of IAN injury. About 35 patients had resolution of the IAN injury within one month of extraction. The permanent injury was reported for 8 patients, who make up 1.5%. The risk ratio for the IAN injury represents that the patients in the conventional extraction group to have the IAN injury are 10 times those of coronectomy group (Renton *et al.*, 2005; Hatano *et al.*, 2009; Cilasun *et al.*, 2011; Leung & Cheung, 2009; Long *et al.*, 2012). An analysis done by Long *et al.* demonstrates that the risk

ratio for postoperative infection and dry socket is similar between complete extraction and coronectomy (Long et al., 2012). Yet, no difference is found in the postoperative pain level in coronectomy and complete extraction in one week. However there are some limitations in these studies like heterogeneity among studies, limited number of studies, short follow-up, and lack of high-quality researches (Long et al., 2012).

The solutions for the therapy for third molars which are near the IAN are orthodontic extraction (Park et al., 2010), pericoronal ostectomy (Tolstunov, 2010), and removal of the mesial portion of the anatomic crown (Landi et al., 2010). However, these methods should be investigated with large number of studies.

2.9 Research Gap

This study will identify if coronectomy is the possible alternative for extraction of lower third molar. There is another method called sectioning which is easy and quick for extraction of third molar according to Miyamoto *et al.* (2015). This research explores the utilisation of carbide bur and straight low-speed hand piece can lower the scope of complications or any damage that may result in after coronectomy, while decreasing the intraoperative time. This study will also find the scope for failure and success of the coronectomy as an alternative to extracting mandibular third molar.

CHAPTER III: RESEARCH METHODOLOGY

The current chapter elaborates on the kind of methodology that is employed in the current study wherein the chapter further elucidates the search strategy which includes the inclusion and exclusion criteria and PICO approach, design of the study, and data collection in order to assess the postoperative complications that arise after the coronectomy of mandibular third molars is done. With respect to this aim, studies are selected and examined. The present study will be done using a methodology that involves a ‘Narrative Review’. This specific approach would be particularly advantageous in accomplishing the research objectives. The justification of the research design is described as below:

- Using narrative review methodology will be most pertinent so as to elicit the answers to the research questions. The main aim of the narrative review is to find answers to the predefined research questions while making sure that there is no deviation from the study objectives.
- The narrative review approach is most reasonable for the researcher with regards to funds and time and allows the research scholar to complete the study within a fixed duration of six months of time.

The approach adopted for this study, as stated earlier, involves a narrative review that is simply a non-systematic review which aspires to identifying and outlining the findings of studies conducted in the past without actually reproducing them. By means of a narrative review, the research scholar also aims to identify the suitable areas for further research on the chosen topic. Hence, these would relate to areas or aspects that have not been studied in the past or as on date (Cronin et al., 2008; Grant & Booth, 2009). A typical narrative review should be structured, identifying materials and the literature should cover wide range of subject matter covering a wide range of subject matter, and synthesize the available evidence pertaining to the topic in the form of textual, tabular or graphical form, and convey a clear message from the perspective of research questions (Grant & Booth, 2009). In this research, researcher identified articles that are highly relevant to the study objective which focuses on the postoperative complications that arise after the coronectomy of mandibular third molars. The format in this study was based on a chronological sequencing of the research summary where the current trends would be recognized and outlined. This format would also include establishing the contextual framework that would aid the researcher in bifurcating the

contents into dependent and independent variables along with their associations (Green et al., 2006; Randolph, 2009).

3.1 Search Strategy

3.1.1 Inclusion Criteria

Studies in which -

- The patients who were identified to have enhanced scope of risk for inferior alveolar nerve injury, which could be understood through radiography (OPT or CBCT); particularly including the criteria for high risk of nerve injury; inferior alveolar canal experiencing displacement at the roots; narrow inferior alveolar canal; radiolucent periapical area; third root molar narrowing; darkening, curving of third molar roots, interruption and loss of lamina dura of nerve canal.
- Including the patients who experienced any of the following conditions in their lower third molars such as periodontal disease of second mandibular molar, follicular or any clinical condition that does not impact the tooth vitality and pericoronitis.
- Studies where follow-up with regards to the clinical outcomes following the surgery was higher than two months.

3.1.2 Exclusion Criteria

Studies in which -

- Case series, case reports, studies that included less than 10 subjects, expert opinion, comments, reviews, letters to editors and studies that analysed the existing sample of a study that was pre-existing.
- Studies in which patients were excluded in case they exhibited the following symptoms; clinical indications for systemic infection, conditions that were medically compromised owing to diabetes, previous radiotherapy or chemotherapy, bone disease (osteoporosis), immunological diseases, prevalent neural disorders, already existing inferior alveolar nerve deficit, prevalent neural disorders and patients younger than 16 years old.

3.1.3 PICO Approach

Patient or population:	Patients whose third molars are close or in contact with IAN
Intervention:	Coronectomy
Comparison:	Complete removal versus coronectomy
Outcome:	IAN injury and the occurrence of other post-operative complications

3.2 Study Design

The study design of the narrative review is possible due to various advantages. First and foremost, a narrative review approach takes into account and understands the multiplicities and ranges of an assortment of research articles while considering the scope for a practice that is reflective, self-knowledge and acknowledgement (Jones, 2004). The appropriateness of the study design of the narrative review lies in the fact that it can be utilized for researches that involve extensive topics (Collins & Fauser, 2005). In addition, a narrative review favours the establishment of an association amongst diverse research areas and aspects so as to obtain an in-depth insight into the research setting on the whole. The following reasons can be attributed to the choice of a study design which is narrative in its structure.

- This current research warrants the need to examine and evaluate the complications that arise following a coronectomy procedure that would also take into account the necessity to extensively assess the varying success and failure rates following a coronectomy. The purpose will be specifically served, when the investigator assesses already existing study pertaining to postoperative complications that can arise after the coronectomy is done.
- Moreover, in special circumstances, it is not feasible for the coronectomy procedure to be applied. Hence, it also necessitates the identification of situations where it is not possible or inappropriate to choose the coronectomy procedure. This issue can also be resolved by means of a narrative review approach.

3.3 Data Collection

The main aim of each narrative review is to find every study that has been executed and published in the past while ensuring that it pertains to the objectives of the existing research. Predictably, researchers who are known to do narrative reviews more often than not encounter variations in the way how or whether a specific study was published or with regards to the manner in which the elements of the study is described in the literature or catalogued by myriad organizations (Relevo, 2012). A narrative review commonly aims to surpass any such obstacles so as to outline all studies which are suitable while taking into account any limitations that can arise due to time and resources. Identifying relevant literature mostly aims to establish a balance between finding such literature and its preciseness that would mean the quantum of literature that is actually relevant (Wallace et al., 2014). However, it is the context of the research that is important in obtaining an optimal balance.

Specifically, the data for this narrative review research will be gathered from the primary sources such as data derived from the actual research and from the secondary sources which would involve identifying studies that are pertinent to the current study from leading journals such as Science Direct, PubMed, Wiley Online, Elsevier, Cochrane Library and any relevant and reputed scientific journals.

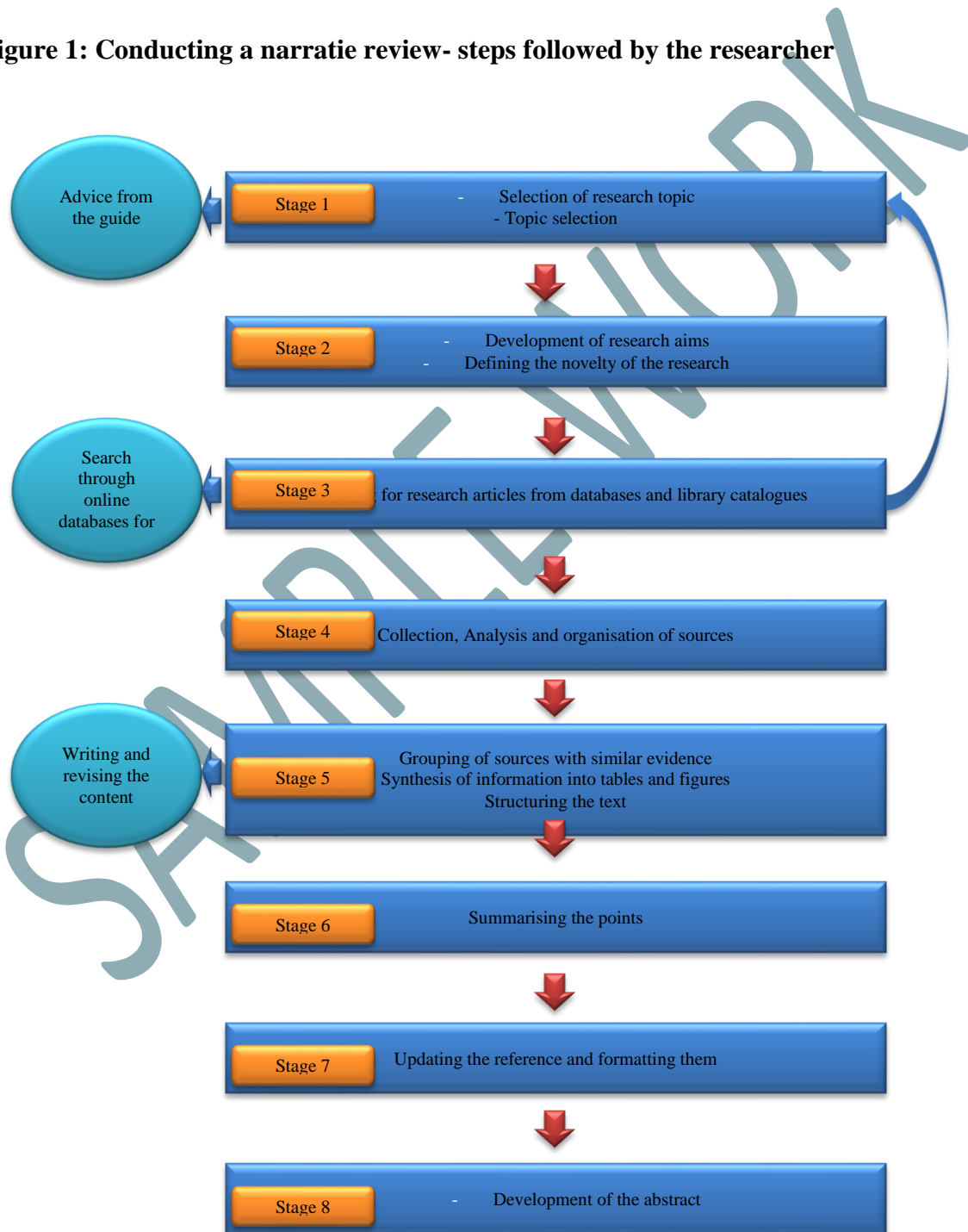
3.4 Critical Appraisal Skills Programme (CASP) Assessment of included studies

In order to identify methodological flaws (such as quality and utility) in the literature and also to offer informed decisions about the quality of research evidence, there are several critical appraisal tools are available. However, choosing the right tool is an important component of evidence based practice. Although there are several tools (Clarke & Oxman, 2003; Crombie, 1996; NHMRC, 1999) have been acknowledged but there is no consensus regarding its gold standard. In this research, CASP was used as it was more appropriate in ask three important questions such as whether the study is valid, the findings and how the results helps locally. Therefore, in the present research, methodological assessment of the quality of review was performed using the Critical Appraisal Skills Programme (CASP) (CASP, 2013). For the present research, the CASP tool is used to assess whether the studies selected for the review are suitable for narrative review considering the reliability and significance of the results. The CASP items consists of 10-12 questions and this was presented in Appendix 1.

In brief, the question 1 discuss about the clarity in the aims, followed by methodology appropriateness, research design, recruitment strategy, data collection, relationship between researcher and participants, ethical issues, analysis rigor, clear findings and finally whether the research are valuable.

Further, the study also adhered following steps in writing a narrative review which is based on the steps devised by Green et al. (2006).

Figure 1: Conducting a narratie review- steps followed by the researcher



Source: Adopted from Gasparyan et al. (2011)

3.5 Summary

The present chapter focused on the method of the research. The current research justified the choice of narrative review for the present research with the research purposefully focussing on the assessment of postoperative complication after coronectomy of mandibular third molar is done.

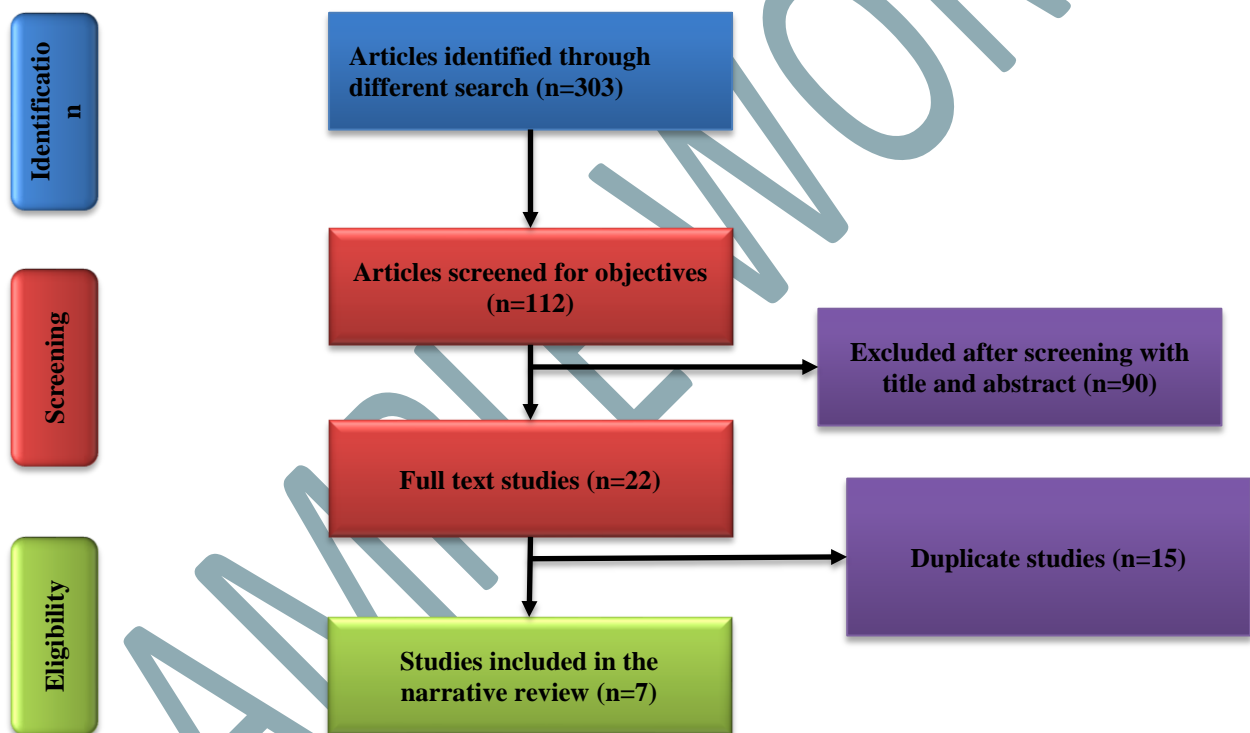
SAMPLE WORK

CHAPTER IV: RESULTS

4.1 Introduction

Based on the inclusion and exclusion criteria set, the present research considered studies which were selected after in-depth analysis. The present research hence considered 9 studies for the narrative review. Following is the data extraction chart (figure 1) which summarises the search process and how studies are filtered and selected for the narrative review.

Figure 2: Flow chart depicting the selection of studies for narrative review



In this research, around 303 studies were identified to have relevance to the research topic wherein the articles screened for the objectives further brought down the number to 112. Further screening revealed that only 22 researches were related for the analysis in the narrative review as 90 records were screened based on their title and abstract. Furthermore, the duplicate studies were identified after careful analysis and 15 studies were excluded. Hence, only 7 studies suited the specific criteria which dealt with the exploration of postoperative complication after coronectomy of mandibular third molars. Therefore, the present research which is a narrative review to examine the complications that occur in postoperative period post the coronectomy procedure of mandibular third molars considers 7

studies for the narrative review. Quality assessment using CASP and other tools for different study types are shown in the Research Methodology section.

For the evaluation of the studies considered in the present research, the Critical Appraisal Skills Programme (CASP) tool for is the Randomised Control trials considered. However, for the studies which had considered Pre-Post design, the Quality Assessment Tool developed by National Institutes of Health (2014) is used. The CASPs for the randomised control study and cohort studies and the Quality assessment for the Pre-post studies are presented below. After the quality assessment, all the studies considered for the review were thematically examined wherein the themes are as follows:

- i) Description of the studies
- ii) Outcomes of Coronectomy of Wisdom tooth
- iii) Rate of failure and success of Coronectomy
- iv) Coronectomy as an alternative for MTM

Table 1: Quality assessment for Pre post study (National Institutes of Health, 2014)

Criteria	Gady and Fletcher (2013)	Mukherjee et al. (2016)	Leung and Cheung (2016)	Kouwenberg et al. (2016)
1. Was the study question or objective clearly stated?	No	Yes	Yes	Yes
2. Were eligibility/selection criteria for the study population prespecified and clearly described?	Yes	Yes	Yes	Yes
3. Were the participants in the study representative of those who would be eligible for the test/service/intervention in the general or clinical population of interest?	Yes	Yes	Yes	Yes
4. Were all eligible participants that met the prespecified entry criteria enrolled?	Yes	Yes	Yes	Yes
5. Was the sample size sufficiently large to provide confidence in the findings?	No	Yes	Yes	Yes
6. Was the test/service/intervention clearly described and delivered consistently across the study population?	Yes	Yes	Yes	Yes
7. Were the outcome measures prespecified, clearly defined, valid, reliable, and assessed consistently across all study participants?	Yes	Yes	Yes	Yes
8. Were the people assessing the outcomes blinded to the participants' exposures/interventions?	Not revealed	Not revealed	Not revealed	Not revealed
9. Was the loss to follow-up after baseline 20% or less? Were those lost to follow-up accounted for in the analysis?	Not revealed	yes	Not revealed	yes
10. Did the statistical methods examine changes in outcome measures from before to after the intervention? Were statistical tests done that provided p values for the pre-to-post changes?	No	No	Yes	Yes
11. Were outcome measures of interest taken multiple times before the intervention and multiple times after the intervention (i.e., did they use an interrupted time-series design)?	No	Yes	Yes	Yes
12. If the intervention was conducted at a group level (e.g., a whole hospital, a community, etc.) did the statistical analysis take into account the use of individual-level data to determine effects at the group level?	No	No	No	No

Table 2: Quality assessment for Cohort study using CASP

Q. No	Checklist questions	Leung and Cheung (2012)
1	The study addresses an appropriate and clearly focused question.	Yes
2	The two groups being studied are selected from source populations that are comparable in all respects other than the factor under investigation.	Yes
3	The study indicates how many of the people asked to take part did so, in each of the groups being studied.	No
4	The likelihood that some eligible subjects might have the outcome at the time of enrolment is assessed and taken into account in the analysis.	Can't tell
5	What percentage of individuals or clusters recruited into each arm of the study dropped out before the study was completed.	12.9%
6	Comparison is made between full participants and those lost to follow up, by exposure status.	Can't tell
7	The outcomes are clearly defined.	Yes
8	The assessment of outcome is made blind to exposure status. If the study is retrospective this may not be applicable.	Can't tell
9	Where blinding was not possible, there is some recognition that knowledge of exposure status could have influenced the assessment of outcome.	Can't tell
10	The method of assessment of exposure is reliable.	Yes
11	Evidence from other sources is used to demonstrate that the method of outcome assessment is valid and reliable.	Yes
12	Exposure level or prognostic factor is assessed more than once.	Can't tell
13	The main potential confounders are identified and taken into account in the design and analysis.	Yes
14	Have confidence intervals been provided?	No
15	How well was the study done to minimise the risk of bias or confounding?	High quality
16	Taking into account clinical considerations, your evaluation of the methodology used, and the statistical power of the study, do you think there is clear evidence of an association between exposure and outcome?	Yes
17	Are the results of this study directly applicable to the patient group targeted in this guideline?	Yes

Table 3: Quality assessment for Randomised Control studies using CASP

Q. No	Checklist questions	Genu and Vasconcelos (2008)	Renton <i>et al.</i> (2005)
1	The study addresses an appropriate and clearly focused question.	Yes	Yes
2	The assignment of subjects to treatment groups is randomised.	Yes	Yes
3	An adequate concealment method is used.	Can't tell	Can't tell
4	The design keeps subjects and investigators 'blind' about treatment allocation.	No	Can't tell
5	The treatment and control groups are similar at the start of the trial.	Yes	Yes
6	The only difference between groups is the treatment under investigation.	Yes	Yes
7	All relevant outcomes are measured in a standard, valid and reliable way.	Yes	Yes
8	What percentage of the individuals or clusters recruited into each treatment arm of the study dropped out before the study was completed?	Can't tell	Can't tell
9	All the subjects are analysed in the groups to which they were randomly allocated (often referred to as intention to treat analysis).	Can't tell	Can't tell
10	Where the study is carried out at more than one site, results are comparable for all sites.	Can't tell	Can't tell
11	How well was the study done to minimise bias?	High quality	High quality
12	Taking into account clinical considerations, your evaluation of the methodology used, and the statistical power of the study, are you certain that the overall effect is due to the study intervention?	Yes	Yes
13	Are the results of this study directly applicable to the patient group targeted by this guideline?	Yes	Yes

4.2 Description of the studies

The present research considered a total of 7 studies for narrative reviewing wherein 4 studies come under the pre-post study, one as a cohort study and two as randomised controlled studies. The 4 pre-post studies considered for the review were conducted by Gady and Fletcher (2013), Mukherjee *et al.* (2016), Leung and Cheung (2016) and (Kouwenberg *et al.*, 2016). In the study by Gady and Fletcher (2013), an examination of the impact of coronectomy on the elevated risk for injury to the inferior alveolar nerve was examined in 6 select patients with the history of pericoronitis and tooth carries. The research which did not reveal the inferences of the methodology adopted or the number of patients selected for the research in specific however attempted to analyse whether coronectomy is a viable alternative treatment technique for the impaction of third- molar. However, the study by Mukherjee *et al.* (2016) was well established with specific aim, the methodology adopted, the number of patients considered and the evaluation of the patients post operation during follow-up. In the study by Leung and Cheung (2016) which is one another pre-post study considered the monitoring of the long-term morbidities that are associated with lower third molars coronectomy up to 5 years and its impact on inferior alveolar nerve (IAN). However, the fourth pre-post study considered in the research which was conducted by Kouwenberg *et al.* (2016) evaluated the impact of coronectomy on the mandibular canal wherein the effects of coronectomy on IAN was recorded.

One cohort study by Leung and Cheung (2012) attempted to examine whether Coronectomy is safe within the first 3 years post operation and its impact on IAN considering the migration pattern of the retained roots after coronectomy. Other studies considered were Randomised control trials by Genu and Vasconcelos (2008) and Renton *et al.* (2005) which examined the prospects of tooth section technique and Coronectomy respectively. The selection of the research conducted by Genu and Vasconcelos (2008) is to examine whether other techniques for mandibular tooth extraction are feasible or not and to conclude the better effects of Coronectomy.

Table 4: Study characteristics

Author name and year	Title	Study type	Study population	Age group	Patient description	Outcomes of the research	Conclusion
Gady and Fletcher (2013)	Coronectomy: indications, outcomes, and description of technique	Pre- post study	6 patients	40-70 years	elevated risk for injury to the inferior alveolar nerve	no increase in the incidence of infection, pain, development of abnormalities, and root eruption after 12 months and no migration of roots after 24 months post operation	coronectomy is a reasonable treatment alternative for appropriately selected patients thought to be at elevated risk for IAN injury associated with extraction of third molars.
Mukherjee <i>et al.</i> (2016)	Evaluation of Outcome Following Coronectomy for the Management	Pre- post study	18 patients Male= 13 Female= 5	18 to 40 years	patients with high risk of injury to IAN	None of the patients considered in the research had IAN injury and none	Coronectomy procedure is effective in controlling inferior alveolar nerve injury following third molar surgery, in radiographically

	of Mandibular Third Molars in Close Proximity to Inferior Alveolar Nerve					required second surgical removal	evaluated high risk cases and it has very low incidence of complications.
Leung and Cheung (2016)	Long-term morbidities of coronectomy on lower third molar.	Pre- post study	458 Male: 172 Female: 286	Mean age= 28	Patients with Darkening of third molar root, Abrupt narrowing of third molar root, Interruption and loss of the white line(s) of inferior alveolar canal (IAC), Displacement of the IAC by the root, and Abrupt narrowing of one or both of the canal white line	There were incidence of pain after 6 months post operation. However, Re-operation to remove the exposed root did not cause any IAN deficit.	Lower third molar coronectomy is safe in long term.

					representing the IAC		
Kouwenberg <i>et al.</i> (2016)	Coronectomy of the mandibular third molar: Respect for the inferior alveolar nerve	Pre- post study	191 Male: 76 Female: 115	12-81 years	Eruption of the mandibular third molar	None of the patients exhibited inferior alveolar nerve injury	coronectomy can be a reliable alternative to complete removal of the impacted mandibular third molar in patients exhibiting an increased risk of damage to the inferior alveolar nerve on panoramic radiographs
Leung and Cheung (2012)	Coronectomy of the lower third molar is safe within the first 3 years.	Cohort study	98 Male: 35 Female: 68	Mean age: 25.7 years	darkening of the root abrupt narrowing of the root interruption and loss of the white line representing the inferior alveolar	Root eruption causing sensitivity occurred in 3% of the patient sample wherein erupted roots were removed. None of the reoperated cases presented	retained roots after coronectomy in the lower third molars produce no complications in terms of infection, pain, or the development of pathologies

					canal displacement of the inferior alveolar canal by the roots abrupt narrowing of 1 or 2 of the white lines representing the inferior alveolar canal	with a postoperative inferior alveolar nerve deficit.	
Genu and Vasconcelos (2008)	Influence of the tooth section technique in alveolar nerve damage after surgery of impacted lower third molars	Randomised control studies	25 patients	21-34		There was no association between deformities of the tip of dental needles and nerve injury	diminished incidence of IAN injury or the presence of radiographic signs of a direct relationship between the tooth/nerve/mandibular canal and IAN injury.
Renton <i>et al.</i>	A randomised	Randomised	128	Mean	patients who were	No root required	Coronectomy reduces the

(2005)	controlled clinical trial to compare the incidence of injury to the inferior alveolar nerve as a result of coronectomy and removal of mandibular third molars	control studies	patients	age: 28	judged to be at high risk of injury to the inferior alveolar nerve based on radiographic features	removal or reoperation	incidence of injury to the inferior alveolar nerve without increasing the risk of dry socket or infection
--------	---	-----------------	----------	------------	---	------------------------	---

SAMPLE WORK

4.3 Outcomes of Coronectomy of Wisdom tooth

The outcomes of coronectomy of the wisdom tooth were examined firstly from the lenses of the pre-post studies considered in this research. According to the study done by Gady and Fletcher (2013), coronectomy is described as a reasonably safe alternative treatment for the patients who have increased risk for inferior alveolar nerve injury with the extraction of mandibular third molar teeth. The study which combined an extensive review of previous literature and the examination of select cases revealed that coronectomy can be a reasonable and safe alternative treatment procedure for patients who are on the verge of injury to the IAN with the removal of the third molars. The study considered the findings of previous researches in the literature with 12 month post-operative follow-up that revealed no infection, pain or abnormalities whereas no migration in the root was witnessed in studies that had 24 and 36 month follow-up. Though the research considered patients in the age group of 40- 70 years, the research revealed that Coronectomy is appropriate for patients above 25 years which was substantiated using previous researches. However, in the study by Mukherjee *et al.* (2016), it was revealed that among the 18 patients considered for the research, none of the patients required an additional surgical removal or injury in the IAN due to Coronectomy. Hence, the study recorded no post-operative infection incidence as its outcome with no second surgical intervention. However, some patients developed post-operative side effects associated with coronectomy. Another study by Leung and Cheung (2016) considered a large sample size with 458 patients wherein the prevalence of IAN injury was recorded. It was revealed that the injury was less than 1 per cent (0.16 per cent) and was witnessed to be temporary. Since the sample size was large, the researcher witnessed one case of Long-term postoperative infection after 6 months post-operation and another case at 1 year post operation. However, there were no infections found after 12 months post-operation. Only 2.3 cases of the total 612 coronectomies had root exposure; however, the study by Leung and Cheung (2016) did not record any re-operation due to the exposed root which had not effects on the IAN. The study by Kouwenberg *et al.* (2016) which examined 151 patients that had coronectomy were followed with clinical examinations which revealed that some patients had eruption of the retained root which necessitated second surgical procedure. However, such cases were sparse and hence could act as an alternative to common impaction of the mandibular tooth.

However, one cohort study by Leung and Cheung (2012) which considered 98 patients for the research revealed no infection or abnormalities post coronectomy. No pathology or root eruption was witnessed; however the study recorded some cases of re-operation with no presentation of postoperative inferior alveolar nerve deficit revealing the effectiveness of coronectomy. In addition, the two RCTs considered had different hypotheses to prove. The study by Genu and Vasconcelos (2008) was considered by the researcher even though the research did not account to the examination of the efficiency of Coronectomy on the following grounds- the study considered a technique called tooth section technique which might damage the IAN and hence the research can be used as a comparative basis. The research which considered a sample size of 25 patients with 50 lower third molars revealed IAN injury in 8 per cent of patients; however this does not account to the technique used which is proven using statistical techniques. Furthermore, the researcher could not prove the association between IAN injury and tooth/nerve/mandibular canal. However, Renton *et al.* (2005) is another RCT which compared the incidence injury to IAN due to Coronectomy wherein the research considered 128 patients requiring removal of mandibular third molars. The study recorded no reoperation or removal even though there were damages in the nerves post operation.

4.4 Rate of failure and success of Coronectomy

Almost all researches considered for the review recorded the rate of success and failure of coronectomy. However, the study by Gady and Fletcher (2013) does not reveal the failure in the cases considered. Still, all cases considered in the research were to some extent had better effects of Coronectomy which can be considered the success of coronectomy. However, there were failure cases in other studies, The study by Mukherjee *et al.* (2016) revealed two of the patients to have failed coronectomy which is associated with the migration of roots which led to the removal of the roots. In addition, there were other adverse cases; one patient developed intra-operative bleeding profusely in the failed case wherein one patient had paresthesia in the temporary lingual nerve. However, the research by Leung and Cheung (2016) recorded one case of failure at the adjacent second molar which caused mild discomfort in the third molar which further led to the removal of the root retained; however, this was after 36 months post operation and a reoperation was facilitated. No failure cases of Coronectomy were recorded in the study by Kouwenberg *et al.* (2016).

However, in the prospective cohort study by Leung and Cheung (2012) no cases of failure were recorded. In the RCT by Renton *et al.* (2005), there were 36 cases of failed coronectomy wherein the study further recorded the risk of failure to be high in women cases which is proven by its high probability value. Failed cases were due to the formation of the conical root and root narrowing which are evident from the radiographic examination.

4.5 Coronectomy as an alternative for MTM

Almost all studies reveal Coronectomy as a safe alternative for the removal of third molars in patients with high risk of IAN injury; however each study has its own implications. Firstly, the study by Gady and Fletcher (2013) revealed the appropriateness of the treatment method in patients above 25 years and those who are of low tolerance for post treatment neurosensory deficit possibility during the time of consultation. However, the success of Coronectomy according to the previous researcher is associated with the assessment of follow-ups periodically and the compliance of patients which is incremental for the procedure to act as an alternative for MTM. Mukherjee *et al.* (2016) asserted the effectiveness of Coronectomy towards controlling the injury of IAN after the surgery of the third molar as the procedure has low incidence of complications and can be used even in high risk cases. The research by Leung and Cheung (2016) conducted as a prospective pre-post study reveals the reduced morbidities of the technique which is associated with pain, infection, pathologies' development, and dry socket. Since temporary risks were recorded during the research, the study discerned that Coronectomy could act as a long-term safe treatment method for the management of the impacted lower third molars with high IAN injury risks. Kouwenberg *et al.* (2016) stated that Coronectomy could be used as a viable alternative to the complete third molar removal since such a removal tend to cause irritation of the IAN. According to the previous research, even in the elderly population, there were no cases of paresthesia or anesthesia developed after Coronectomy. In addition, the results of the research reveal that coronectomy can be used in patients with high risks of IAN injury.

Leung and Cheung (2012) confirmed that the roots retained after Coronectomy of the lower third molars had developed no complications with respect to pain, infections or pathology development within the first 3 years of the follow-up. Though root eruption is the case in some

patients, it is proven that Coronectomy is a safe technique and can be used as an alternative technique to complete removal of the third molar. However, the research by Renton et al. (2005) asserted that the chances of IAN injury and adverse effect on morbidity were reduced in the case of Coronectomy. Furthermore, no significant association with the canal deviation was witnessed after coronectomy and hence Coronectomy is deemed a viable alternative technique to surgical complete removal of third molar.

4.6 Summary

In the present chapter, the various researches considered for the narrative review were selected and were analysed based on themes. The themes are generated on the basis of the research objectives wherein the important findings of the researches in terms of the outcomes of Coronectomy of Wisdom tooth, Rate of failure and success of Coronectomy, and Coronectomy as an alternative for MTM were elaborated.

CHAPTER V – DISCUSSION AND CONCLUSION

5.1 Introduction

The present research assessed the postoperative complications of coronectomy procedure done on the mandibular third molar (MTM). The term ‘coronectomy’ emerged in the year 1984 when Ecuyer and Debien described the coronectomy procedure as a different method for the conventional removal of third molar teeth (Ecuyer & Debien, 1984). After that, with respect to the technique, efficiency, and result of the coronectomy, many reports have come up. The risk of treatment-related injury to the IAN can be considerably reduced with coronectomy in addition to less complexity associated with the procedure. The objective of this procedure is to reduce the incidence of IAN injury due to the removal of third molar. Hence, the determination of IAN incidence is very important. After the removal of third molar, the frequency of IAN injury is from 0.4% to 8.4% (Smith et al., 1997; Rood & Shehab, 1990; Sisk et al., 1986; Gülicher & Gerlach, 2001). The candidates of surgical extraction of mandibular teeth will undergo panoramic radiographs conventionally. The relationship of the tooth to the IAN can be evaluated using CT scan in 3 dimensions; however, there is some hesitation due to the cost and exposure to radiation. The indicators for IAN damage are narrowing of apices, darkening of root, narrowing of IAN canal, diversion of IAN canal, and interruption of white line of IAN canal (Smith et al., 1997; Sedaghatfar et al., 2005). Coronectomy can reduce the injury to the IAN. About 50 coronectomy procedures were done on 41 patients by Pogrel et al. (2004). These patients had risk of IAN injury from panoramic evaluation. After these procedures by these researchers, there was no postoperative IAN involvement.

The intentional coronectomy is another method to avoid IAN injury. Coronectomy is used by the doctors (Pogrel *et al.*, 2004; Renton *et al.*, 2005; Ramaraj, 2008) to safeguard the IAN for mesioangular and vertical bony impacted mandibular third molar teeth. The possibility of a second operation for the root removal, unsatisfactory healing, and infection of retained roots are the disadvantages of the coronectomy (Renton *et al.*, 2005; Ramaraj, 2008; Dolanmaz *et al.*, 2009). For the tooth ankyloses, this method is an optimal technique because the orthodontic extraction technique is inefficient (Bonetti *et al.*, 2007; Ramaraj, 2008). However, coronectomy is not the best method for all mandibular third molar teeth. It is essential to exclude the infected

teeth and mobile teeth, since remnants of the root can act like foreign bodies. The coronectomy may not be suitable for the teeth that are horizontally impacted along the mandibular canal as the sectioning of such tooth could harm the nerve (Dolanmaz *et al.*, 2009).

In this regard, the researcher considered the method of narrative reviewing to examine the effectiveness of this alternative method for the removal of mandibular third molar with the implication that the effects of the method should be examined in association with the injury of the IAN. Inclusion and Exclusion criteria were set by the researcher to screen papers wherein only 7 studies were considered for the review which comprised of pre-post studies, RCTs and cohort studies.

5.2 Summary of findings

All select researches considered in the present study almost revealed the same notion- Coronectomy as a viable alternative to the impaction of mandibular third molar. A prospective cohort study was done in order to prove that in the first three years, the coronectomy of the lower third molar is harmless (Leung & Cheung, 2012). In this RCT study, the patients who had coronectomy were examined. Postoperatively, these patients were evaluated periodically for about 36 months for infection, root eruption, pain, another surgery for the root removal, and the pathology that the patients may have developed at this time (Leung & Cheung, 2012). About 108 patients had 155 coronectomies, which were successful. About 98 patients finished the follow-up, which totalled to 135 coronectomies. Antibiotics and debridement were considered for the six patients, who developed the infection within the first week. About 58 patients who made 43% of the total patients felt postoperative pain in the first week. About 4 patients complained of subsequent pain, who had roots that were exposed. They were sensitive to water and cold food (Leung & Cheung, 2012). Root eruption of lower third molar happened for four patients and in order to extract the retained root, reoperation was done. After the reoperation, there was no IAN injury or any other morbidity. The mean age of the patient with root eruption was higher than mean age of the patients without root eruption.

Another prospective study Genu and Vasconcelos (2008) examined about 120 patients (175 teeth) by means of CT. These patients were examined using CT and the factor that the patients with or without cortical bone between the inferior alveolar canal and the root was

considered to separate the patients between the extraction (n=87) and coronectomy (n=88) respectively (Genu & Vasconcelos, 2008).

The extraction group had 95.4% success rate whereas the coronectomy group had 95.5%. After 17 months, the patients were followed. At this time, in the extraction group, 2 patients experienced IANI, which resolved in one month. Also in the extraction group, one complaint of dry socket was found. In the coronectomy group, for one postoperative month, one patient had minor infection. Antibiotics and subgingival irrigations were used to treat this. In this study, two coronectomies failed (Genu & Vasconcelos, 2008). The inference from this research is that the coronectomy is the preferable choice over the extraction because there were fewer problems. Thus the coronectomy is recommended for the impacted mandibular molar extraction in light of IANI.

In order to compare the occurrence of IANI because of coronectomy and removal mandibular third molar, a randomized control clinical trial was done (Renton *et al.*, 2005). About 128 patients were taken for this study. Proximity to IAN was found out in the radiological evidence. These patients were receiving extraction or coronectomy for the extraction of mandibular third molar randomly. As the roots displaced postoperatively, two subgroups were formed because of failed coronectomy (Renton *et al.*, 2005). The candidates were followed at 25 months. About 19 patients who made up 19% had IANI after the extraction of third molar. IANI was also reported in 3 patients, who made up 8% in the coronectomy group. For these 3 patients, coronectomy was unsuccessful because of mobility of roots after the coronectomy. Normally, IAN will be away from the mobilization of the roots; however, when the nerve is damaged, this causes IAN neuropathy (Renton *et al.*, 2005). Successful coronectomy resulted in no IANI because the IAN was not interfered. In this study, it was observed that there was no incidence of lingual nerve injury. Moreover, there was equal occurrence of dry socket in all the groups. But the soft tissue infections were reported by three patients in the coronectomy procedure group and one patient in the extraction group. The cause of the soft tissue infection was reported due to the preservation of the remaining root after the coronectomy procedure.

Kouwenberg *et al.* (2016) further asserted Coronectomy as an alternative to the complete removal of the impacted mandibular third molar in the cases where the mandibular canal and

tooth roots have a close relationship. Coronectomy can be utilised as an alternative to the complete removal of the impacted mandibular third molar teeth for the patients with IAN vulnerability on the panoramic radiograph. In the study by Leung and Cheung (2016) on long term morbidities after the coronectomy of the lower third molars, about 612 lower third molar coronectomy procedures for 458 patients were done. IAN injury did not happen even after the reoperation for the removal of exposed root. On the whole, the inferences acquired from the examination of previous researches reveals that Coronectomy can be a viable technique for the treatment of the Mandibular Third Molar without affecting the IAN.

5.3 Strengths and limitations of the study

The present research has the following strengths: this is a novel approach that attempted to address the queries of the research community regarding the safety of conducting coronectomy. The findings of the present research give an overall idea about the procedure wherein the implications are also depicted based on the results of the previous researches conducted. However, there are certain limitations. Firstly, the researcher is restricted to select only 7 studies based on the availability of sources and hence the study reviewed only 7 papers. Secondly, the researcher in the beginning used two systematic reviews based studies which provided better insights; however, reviewing a review paper will not be an appropriate case and hence the two systematic review papers were removed from narrative reviewing. However, future researches can consider an even more large sample size (meaning the number of studies for review) to arrive at better consensus. However, this requires more researches in the future to come.

5.4 Conclusion

Injury to the inferior alveolar nerve is the most important problem while extracting the mandibular third molars. In this respect, coronectomy proves to be an effective and probably more beneficial alternative in many cases. Like any other procedure, there are certain advantages and disadvantages that require to be taken into account to measure the efficiency of this procedure. As seen in the above sections, there are some postoperative complications that surface

with coronectomy, which cannot be discounted. Hence, it is recommended that further researches require to be conducted so as to assess the long-run benefits of coronectomy.

Reference

AAOMS (2017). *American Association of Oral and Maxillofacial Surgeons*.

[Online]. 2017. Management of Third Molar Teeth. Available from:

http://www.aaoms.org/docs/govt_affairs/advocacy_white_papers/management_third_molar_white_paper.pdf. [Accessed: 24 June 2017].

Ahmed, C., Wafae, E.W. & Bouchra, T. (2011). Coronectomy of third molar: a reduced risk technique for inferior alveolar nerve damage. *Dental update*.

[Online]. 38 (4). p.pp. 267–8, 271–2, 275–6. Available from:

<http://www.ncbi.nlm.nih.gov/pubmed/21714408>.

Alfredo, E., Marchesan, M.A., Sousa-Neto, M.D., Brugnera-Júnior, A. & Silva-Sousa, Y.T.C. (2008). Temperature variation at the external root surface during 980-nm diode laser irradiation in the root canal. *Journal of Dentistry*.

[Online]. 36 (7). p.pp. 529–534. Available from:

<http://linkinghub.elsevier.com/retrieve/pii/S0300571208001048>.

Bataineh, A.B. (2001). Sensory nerve impairment following mandibular third molar surgery. *Journal of oral and maxillofacial surgery : official journal of the American Association of Oral and Maxillofacial Surgeons*. 59 (9). p.p. 1012–7; discussion 1017.

Bonetti, G.A., Bendandi, M., Laino, L., Checchi, V. & Checchi, L. (2007).

Orthodontic extraction: riskless extraction of impacted lower third molars close to the mandibular canal. *Journal of oral and maxillofacial surgery : official journal of the American Association of Oral and Maxillofacial*

Surgeons. [Online]. 65 (12). p.pp. 2580–6. Available from:
<http://www.ncbi.nlm.nih.gov/pubmed/18022488>.

Bonetti, G.A., Parenti, S.I. & Checchi, L. (2008). Orthodontic extraction of mandibular third molar to avoid nerve injury and promote periodontal healing. *Journal of clinical periodontology*. [Online]. 35 (8). p.pp. 719–23. Available from: <http://www.ncbi.nlm.nih.gov/pubmed/18616756>.

CASP (2013). *Casp Checklists*. [Online]. 2013. Available from: <http://www.casp-uk.net/checklists>. [Accessed: 25 July 2017].

Cheung, L.K., Leung, Y.Y., Chow, L.K., Wong, M.C.M., Chan, E.K.K. & Fok, Y.H. (2010). Incidence of neurosensory deficits and recovery after lower third molar surgery: a prospective clinical study of 4338 cases. *International journal of oral and maxillofacial surgery*. 39 (4). p.pp. 320–6.

Chin Quee, T.A., Gosselin, D., Millar, E.P. & Stamm, J.W. (1985). Surgical Removal of the Fully Impacted Mandibular Third Molar: The Influence of Flap Design and Alveolar Bone Height on the Periodontal Status of the Second Molar. *Journal of Periodontology*. [Online]. 56 (10). p.pp. 625–630. Available from: <http://www.joponline.org/doi/10.1902/jop.1985.56.10.625>.

Cilasun, U., Yildirim, T., Guzeldemir, E. & Pektas, Z.O. (2011). Coronectomy in patients with high risk of inferior alveolar nerve injury diagnosed by computed tomography. *Journal of oral and maxillofacial surgery : official journal of the American Association of Oral and Maxillofacial Surgeons*. [Online]. 69 (6). p.pp. 1557–61. Available from:
<http://www.ncbi.nlm.nih.gov/pubmed/21288616>.

Clarke, M. & Oxman, A. (2003). *Cochrane Reviewer's Handbook 420*. Oxford:

The Cochrane Collaboration.

Collins, J.A. & Fauser, B.C.J.M. (2005). Balancing the strengths of systematic and narrative reviews. *Human reproduction update*. 11 (2). p.pp. 103–4.

De Coster, P., Rajasekharan, S. & Martens, L. (2013). Laser-assisted pulpotomy in primary teeth: a systematic review. *International journal of paediatric dentistry*. [Online]. 23 (6). p.pp. 389–99. Available from: <http://www.ncbi.nlm.nih.gov/pubmed/23171469>.

Crombie, I. (1996). *The Pocket Guide to Critical Appraisal: A Handbook for Health Care Professionals*. London: BMJ Publishing Group.

Cronin, P., Ryan, F. & Coughlan, M. (2008). Undertaking a literature review: a step-by-step approach. *British journal of nursing (Mark Allen Publishing)*. 17 (1). p.pp. 38–43.

Dodson, T.B., Cheifetz, I.D., Nelson, W.J. & Rafetto, L.K. (2012). Summary of the proceeding of the Third Molar Multidisciplinary Conference. *Journal of oral and maxillofacial surgery : official journal of the American Association of Oral and Maxillofacial Surgeons*. [Online]. 70 (9 Suppl 1). p.pp. S66-9. Available from: <http://www.ncbi.nlm.nih.gov/pubmed/22916701>.

Dolanmaz, D., Yildirim, G., Isik, K., Kucuk, K. & Ozturk, A. (2009). A preferable technique for protecting the inferior alveolar nerve: coronectomy. *Journal of oral and maxillofacial surgery : official journal of the American Association of Oral and Maxillofacial Surgeons*. [Online]. 67 (6). p.pp. 1234–8. Available from: <http://www.ncbi.nlm.nih.gov/pubmed/19446209>.

Drage, N.A. & Renton, T. (2002). Inferior alveolar nerve injury related to

mandibular third molar surgery: an unusual case presentation. *Oral surgery, oral medicine, oral pathology, oral radiology, and endodontics*. [Online]. 93 (3). p.pp. 358–61. Available from:
<http://www.ncbi.nlm.nih.gov/pubmed/11925548>.

Ecuyer, J. & Debien, J. (1984). [Surgical deductions]. *Actualites odontostomatologiques*. 38 (148). p.pp. 695–702.

Fareed, K., Khayat, R. & Salins, P. (1989). Vital root retention: a clinical procedure. *The Journal of prosthetic dentistry*. 62 (4). p.pp. 430–4.

Frafjord, R. & Renton, T. (2010). A review of coronectomy. *Oral Surgery*. [Online]. p.p. no-no. Available from: <http://doi.wiley.com/10.1111/j.1752-248X.2010.01079.x>.

Freedman, G.L. (1997). Intentional partial odontectomy: Review of cases. *Journal of Oral and Maxillofacial Surgery*. [Online]. 55 (5). p.pp. 524–526. Available from: <http://linkinghub.elsevier.com/retrieve/pii/S0278239197907084>.

Gady, J. & Fletcher, M.C. (2013). Coronectomy: indications, outcomes, and description of technique. *Atlas of the oral and maxillofacial surgery clinics of North America*. [Online]. 21 (2). p.pp. 221–6. Available from:
<http://www.ncbi.nlm.nih.gov/pubmed/23981497>.

Gasparyan, A.Y., Ayvazyan, L., Blackmore, H. & Kitas, G.D. (2011). Writing a narrative biomedical review: considerations for authors, peer reviewers, and editors. *Rheumatology International*. [Online]. 31 (11). p.pp. 1409–1417. Available from: <http://link.springer.com/10.1007/s00296-011-1999-3>.

Geisler, S. (2013). Coronectomy is an effective strategy for treating impacted third

molars in close proximity to the inferior alveolar nerve. *The Journal of the American Dental Association*. 144 (10). p.pp. 1172–1173.

Genu, P.R. & Vasconcelos, B.C.E. (2008). Influence of the tooth section technique in alveolar nerve damage after surgery of impacted lower third molars. *International journal of oral and maxillofacial surgery*. [Online]. 37 (10). p.pp. 923–8. Available from: <http://www.ncbi.nlm.nih.gov/pubmed/18804343>.

Ghaemina, H., Meijer, G.J., Soehardi, A., Borstlap, W.A., Mulder, J., Vlijmen, O.J.C., Bergé, S.J. & Maal, T.J.J. (2011). The use of cone beam CT for the removal of wisdom teeth changes the surgical approach compared with panoramic radiography: a pilot study. *International journal of oral and maxillofacial surgery*. [Online]. 40 (8). p.pp. 834–9. Available from: <http://www.ncbi.nlm.nih.gov/pubmed/21507612>.

Gleeson, C.F., Patel, V., Kwok, J. & Sproat, C. (2012). Coronectomy practice. Paper 1. Technique and trouble-shooting. *The British journal of oral & maxillofacial surgery*. [Online]. 50 (8). p.pp. 739–44. Available from: <http://www.ncbi.nlm.nih.gov/pubmed/22285117>.

Gomes, A.C.A., Vasconcelos, B.C. do E., Silva, E.D. de O., Caldas, A. de F. & Pita Neto, I.C. (2008). Sensitivity and specificity of pantomography to predict inferior alveolar nerve damage during extraction of impacted lower third molars. *Journal of oral and maxillofacial surgery : official journal of the American Association of Oral and Maxillofacial Surgeons*. [Online]. 66 (2). p.pp. 256–9. Available from: <http://www.ncbi.nlm.nih.gov/pubmed/18201605>.

Grant, M.J. & Booth, A. (2009). A typology of reviews: an analysis of 14 review types and associated methodologies. *Health information and libraries journal*.

26 (2). p.pp. 91–108.

Green, B.N., Johnson, C.D. & Adams, A. (2006). Writing narrative literature reviews for peer-reviewed journals: secrets of the trade. *Journal of chiropractic medicine*. 5 (3). p.pp. 101–17.

Gülicher, D. & Gerlach, K.L. (2001). Sensory impairment of the lingual and inferior alveolar nerves following removal of impacted mandibular third molars. *International journal of oral and maxillofacial surgery*. [Online]. 30 (4). p.pp. 306–12. Available from: <http://www.ncbi.nlm.nih.gov/pubmed/11518353>.

Gutknecht, N., Franzen, R., Meister, J., Vanweersch, L. & Mir, M. (2005). Temperature evolution on human teeth root surface after diode laser assisted endodontic treatment. *Lasers in medical science*. [Online]. 20 (2). p.pp. 99–103. Available from: <http://www.ncbi.nlm.nih.gov/pubmed/16007476>.

Hatano, Y., Kurita, K., Kuroiwa, Y., Yuasa, H. & Ariji, E. (2009). Clinical evaluations of coronectomy (intentional partial odontectomy) for mandibular third molars using dental computed tomography: a case-control study. *Journal of oral and maxillofacial surgery : official journal of the American Association of Oral and Maxillofacial Surgeons*. 67 (9). p.pp. 1806–14.

Hillerup, S. (2007). Iatrogenic injury to oral branches of the trigeminal nerve: records of 449 cases. *Clinical oral investigations*. [Online]. 11 (2). p.pp. 133–42. Available from: <http://www.ncbi.nlm.nih.gov/pubmed/17186310>.

Hmud, R., Kahler, W.A. & Walsh, L.J. (2010). Temperature changes accompanying near infrared diode laser endodontic treatment of wet canals. *Journal of endodontics*. [Online]. 36 (5). p.pp. 908–11. Available from:

<http://www.ncbi.nlm.nih.gov/pubmed/20416444>.

Howe, G. & Poynton, H.G. (1960). Prevention of damage to the inferior alveolar nerve during the evaluation of mandibular third molars. *British Dental Journal*. 109. p.pp. 355–363.

Jerjes, W., Upile, T., Shah, P., Nhembe, F., Gudka, D., Kafas, P., McCarthy, E., Abbas, S., Patel, S., Hamdoon, Z., Abiola, J., Vourvachis, M., Kalkani, M., Al-Khawalde, M., Leeson, R., Banu, B., Rob, J., El-Maaytah, M. & Hopper, C. (2010). Risk factors associated with injury to the inferior alveolar and lingual nerves following third molar surgery-revisited. *Oral surgery, oral medicine, oral pathology, oral radiology, and endodontics*. 109 (3). p.pp. 335–45.

Jones, K. (2004). Mission Drift in Qualitative Research, or Moving Toward a Systematic Review of Qualitative Studies, Moving Back to a More Systematic Narrative Review. *The Qualitative Report*. 9 (1). p.pp. 95–112.

Kapila, S., Conley, R.S. & Harrell, W.E. (2011). The current status of cone beam computed tomography imaging in orthodontics. *Dento maxillo facial radiology*. [Online]. 40 (1). p.pp. 24–34. Available from: <http://www.ncbi.nlm.nih.gov/pubmed/21159912>.

Knutsson, K., Lysell, L. & Rohlin, M. (1989). Postoperative status after partial removal of the mandibular third molar. *Swedish dental journal*. 13 (1–2). p.pp. 15–22.

Kohara, K., Kurita, K., Kuroiwa, Y., Goto, S. & Umemura, E. (2015). Usefulness of mandibular third molar coronectomy assessed through clinical evaluation over three years of follow-up. *International journal of oral and maxillofacial*

surgery. [Online]. 44 (2). p.pp. 259–66. Available from:
<http://www.ncbi.nlm.nih.gov/pubmed/25457826>.

Kouwenberg, A.J., Stroy, L.P.P., Rijt, E. d. V.- v.d., Mensink, G. & Gooris, P.J.J. (2016). Coronectomy of the mandibular third molar: Respect for the inferior alveolar nerve. *Journal of Cranio-Maxillofacial Surgery*. [Online]. 44 (5). p.pp. 616–621. Available from:
<http://linkinghub.elsevier.com/retrieve/pii/S1010518216000391>.

Landi, L., Manicone, P.F., Piccinelli, S., Raia, A. & Raia, R. (2010). A novel surgical approach to impacted mandibular third molars to reduce the risk of paresthesia: a case series. *Journal of oral and maxillofacial surgery : official journal of the American Association of Oral and Maxillofacial Surgeons*. [Online]. 68 (5). p.pp. 969–74. Available from:
<http://www.ncbi.nlm.nih.gov/pubmed/20156664>.

Leizerovitz, M. & Leizerovitz, O. (2013). Modified and Grafted Coronectomy: A New Technique and a Case Report with Two-Year Followup. *Case Reports in Dentistry*. 1 (1). p.pp. 1–7.

Leung, Y.Y. & Cheung, L.K. (2012). Coronectomy of the lower third molar is safe within the first 3 years. *Journal of oral and maxillofacial surgery : official journal of the American Association of Oral and Maxillofacial Surgeons*. [Online]. 70 (7). p.pp. 1515–22. Available from:
<http://www.ncbi.nlm.nih.gov/pubmed/22494507>.

Leung, Y.Y. & Cheung, L.K. (2011). Correlation of radiographic signs, inferior dental nerve exposure, and deficit in third molar surgery. *Journal of oral and maxillofacial surgery : official journal of the American Association of Oral*

and Maxillofacial Surgeons. [Online]. 69 (7). p.pp. 1873–9. Available from: <http://www.ncbi.nlm.nih.gov/pubmed/21371801>.

Leung, Y.Y. & Cheung, L.K. (2016). Long-term morbidities of coronectomy on lower third molar. *Oral Surgery, Oral Medicine, Oral Pathology and Oral Radiology*. [Online]. 121 (1). p.pp. 5–11. Available from: <http://linkinghub.elsevier.com/retrieve/pii/S2212440315010913>.

Leung, Y.Y. & Cheung, L.K. (2009). Safety of coronectomy versus excision of wisdom teeth: a randomized controlled trial. *Oral surgery, oral medicine, oral pathology, oral radiology, and endodontics*. 108 (6). p.pp. 821–7.

Lieblich, S.E., Kleiman, M.A. & Zak, J.M. (2012). Parameters of care: clinical practice. Guidelines for oral and maxillofacial surgery (AAOMS ParCare 2012). *Journal of Oral and Maxillofacial Surgery*. 70.

Liu, J. (2006). Effects of Nd:YAG laser pulpotomy on human primary molars. *Journal of endodontics*. [Online]. 32 (5). p.pp. 404–7. Available from: <http://www.ncbi.nlm.nih.gov/pubmed/16631836>.

Loescher, A.R., Smith, K.G. & Robinson, P.P. (2003). Nerve damage and third molar removal. *Dental update*. [Online]. 30 (7). p.pp. 375–80, 382. Available from: <http://www.ncbi.nlm.nih.gov/pubmed/14558203>.

Long, H., Zhou, Y., Liao, L., Pyakurel, U., Wang, Y. & Lai, W. (2012). Coronectomy vs. Total Removal for Third Molar Extraction: A Systematic Review. *Journal of Dental Research*. 91 (7). p.pp. 659–665.

Martin, A., Perinetti, G., Costantinides, F. & Maglione, M. (2015). Coronectomy as a surgical approach to impacted mandibular third molars: a systematic

review. *Head & Face Medicine*. 11 (1). p.p. 9.

Miyamoto, I., Kaneuji, T., Shinya, K., Tsurushima, H. & Yoshioka, I. (2015). A Sectioning Technique for Extraction of Impacted Third Molar by Using a Straight Handpiece and Carbide Bur: Case Report. *Open Journal of Stomatology*. 5 (12). p.pp. 287–292.

Monaco, G., de Santis, G., Gatto, M.R.A., Corinaldesi, G. & Marchetti, C. (2012). Coronectomy: a surgical option for impacted third molars in close proximity to the inferior alveolar nerve. *Journal of the American Dental Association (1939)*. [Online]. 143 (4). p.pp. 363–9. Available from: <http://www.ncbi.nlm.nih.gov/pubmed/22467696>.

Monaco, G., De Santis, G., Pulpito, G., Gatto, M.R.A., Vignudelli, E. & Marchetti, C. (2015). What Are the Types and Frequencies of Complications Associated With Mandibular Third Molar Coronectomy? A Follow-Up Study. *Journal of oral and maxillofacial surgery : official journal of the American Association of Oral and Maxillofacial Surgeons*. 73 (7). p.pp. 1246–53.

Moreno-Vicente, J., Schiavone-Mussano, R., Clemente-Salas, E., Mari-Roig, A., Jane-Salas, E. & Lopez-Lopez, J. (2015). Coronectomy versus surgical removal of the lower third molars with a high risk of injury to the inferior alveolar nerve. A bibliographical review. *Medicina Oral Patología Oral y Cirugía Bucal*. [Online]. p.pp. e508–e517. Available from: http://www.medicinaoral.com/pubmed/medoralv20_i4_p508.pdf.

Mukherjee, S., Vikraman, B., Sankar, D. & Veerabahu, M. subramanian (2016). Evaluation of Outcome Following Coronectomy for the Management of Mandibular Third Molars in Close Proximity to Inferior Alveolar Nerve.

Journal of Clinical and Diagnostic Research. [Online]. 10 (8). p.pp. 57–62. Available from: http://jcdr.net/article_fulltext.asp?issn=0973-709x&year=2016&volume=10&issue=8&page=ZC057&issn=0973-709x&id=8273.

National Institutes of Health (2014). *Quality Assessment Tool for Before-After (Pre-Post) Studies With No Control Group*. 2014. National Institutes of Health.

NHMRC (1999). *How to review the evidence: systematic identification and review of the scientific literature*. [Online]. 1999. NHMRC. Available from: https://www.nhmrc.gov.au/_files_nhmrc/publications/attachments/cp65.pdf. [Accessed: 7 October 2017].

O’Riordan, B.C. (2004). Coronectomy (intentional partial odontectomy of lower third molars). *Oral surgery, oral medicine, oral pathology, oral radiology, and endodontics*. [Online]. 98 (3). p.pp. 274–80. Available from: <http://www.ncbi.nlm.nih.gov/pubmed/15356463>.

Odabaş, M.E., Bodur, H., Barış, E. & Demir, C. (2007). Clinical, radiographic, and histopathologic evaluation of Nd:YAG laser pulpotomy on human primary teeth. *Journal of endodontics*. [Online]. 33 (4). p.pp. 415–21. Available from: <http://www.ncbi.nlm.nih.gov/pubmed/17368330>.

Park, W., Park, J.-S., Kim, Y.-M., Yu, H.-S. & Kim, K.-D. (2010). Orthodontic extrusion of the lower third molar with an orthodontic mini implant. *Oral surgery, oral medicine, oral pathology, oral radiology, and endodontics*. [Online]. 110 (4). p.pp. e1-6. Available from: <http://www.ncbi.nlm.nih.gov/pubmed/20674416>.

- Patel, V., Gleeson, C.F., Kwok, J. & Sproat, C. (2013a). Coronectomy practice. Paper 2: complications and long term management. *The British journal of oral & maxillofacial surgery*. [Online]. 51 (4). p.pp. 347–52. Available from: <http://www.ncbi.nlm.nih.gov/pubmed/22794945>.
- Patel, V., Kwok, J., Sproat, C. & McGurk, M. (2013b). To retrieve or not to retrieve the coronectomy root--the clinical dilemma. *Dental update*. [Online]. 40 (5). p.pp. 370–2, 375–6. Available from: <http://www.ncbi.nlm.nih.gov/pubmed/23909230>.
- Patel, V., Sproat, C., Kwok, J., Beneng, K., Thavaraj, S. & McGurk, M. (2014). Histological evaluation of mandibular third molar roots retrieved after coronectomy. *The British journal of oral & maxillofacial surgery*. [Online]. 52 (5). p.pp. 415–9. Available from: <http://www.ncbi.nlm.nih.gov/pubmed/24684971>.
- Patel, V., Sproat, C., Samani, M., Kwok, J. & McGurk, M. (2013c). Unerupted teeth associated with dentigerous cysts and treated with coronectomy: mini case series. *The British journal of oral & maxillofacial surgery*. [Online]. 51 (7). p.pp. 644–9. Available from: <http://www.ncbi.nlm.nih.gov/pubmed/23522661>.
- Pogrel, M.A. (2009a). An update on coronectomy. *Journal of oral and maxillofacial surgery : official journal of the American Association of Oral and Maxillofacial Surgeons*. [Online]. 67 (8). p.pp. 1782–3. Available from: <http://www.ncbi.nlm.nih.gov/pubmed/19615606>.
- Pogrel, M.A. (2009b). Coronectomy to prevent damage to the inferior alveolar nerve. *The Alpha omegan*. [Online]. 102 (2). p.pp. 61–7. Available from:

<http://www.ncbi.nlm.nih.gov/pubmed/19591330>.

Pogrel, M.A. (2007). Partial odontectomy. *Oral and maxillofacial surgery clinics of North America*. [Online]. 19 (1). p.pp. 85–91, vi–vii. Available from: <http://www.ncbi.nlm.nih.gov/pubmed/18088866>.

Pogrel, M.A., Lee, J.S. & Muff, D.F. (2004). Coronectomy: a technique to protect the inferior alveolar nerve. *Journal of oral and maxillofacial surgery : official journal of the American Association of Oral and Maxillofacial Surgeons*. 62 (12). p.pp. 1447–52.

Ramaraj, P.N. (2008). Orthodontic Extraction: The Riskless Extraction Of the Impacted Lower Third Molars Close to the Mandibular Canal. *Journal of Oral and Maxillofacial Surgery*. [Online]. 66 (6). p.p. 1317. Available from: <http://linkinghub.elsevier.com/retrieve/pii/S0278239108002668>.

Randolph, J.J. (2009). A Guide to Writing the Dissertation Literature Review. *Practical Assessment, Research & Evaluation*. 14 (13). p.pp. 1–13.

Relevo, R. (2012). Chapter 4: effective search strategies for systematic reviews of medical tests. *Journal of general internal medicine*. 27 Suppl 1. p.pp. S28-32.

Renton, T. (2011). Minimising and managing nerve injuries in dental surgical procedures. *Faculty Dental Journal*. [Online]. 2 (4). p.pp. 164–171. Available from: <http://publishing.rcseng.ac.uk/doi/10.1308/204268511X13154691747058>.

Renton, T. (2012). Notes on coronectomy. *British dental journal*. [Online]. 212 (7). p.pp. 323–6. Available from: <http://www.ncbi.nlm.nih.gov/pubmed/22498530>.

- Renton, T. (2013a). Oral surgery: part 4. Minimising and managing nerve injuries and other complications. *British dental journal*. [Online]. 215 (8). p.pp. 393–9. Available from: <http://www.ncbi.nlm.nih.gov/pubmed/24157759>.
- Renton, T. (2013b). Update on coronectomy. A safer way to remove high risk mandibular third molars. *Dental update*. [Online]. 40 (5). p.pp. 362–4, 366–8. Available from: <http://www.ncbi.nlm.nih.gov/pubmed/23909229>.
- Renton, T., Hankins, M., Sproate, C. & McGurk, M. (2005). A randomised controlled clinical trial to compare the incidence of injury to the inferior alveolar nerve as a result of coronectomy and removal of mandibular third molars. *The British journal of oral & maxillofacial surgery*. 43 (1). p.pp. 7–12.
- Robert, R.C., Bacchetti, P. & Pogrel, M.A. (2005). Frequency of trigeminal nerve injuries following third molar removal. *Journal of oral and maxillofacial surgery : official journal of the American Association of Oral and Maxillofacial Surgeons*. [Online]. 63 (6). p.p. 732–5; discussion 736. Available from: <http://www.ncbi.nlm.nih.gov/pubmed/15944965>.
- Rood, J.P. & Shehab, B.A. (1990). The radiological prediction of inferior alveolar nerve injury during third molar surgery. *The British journal of oral & maxillofacial surgery*. [Online]. 28 (1). p.pp. 20–5. Available from: <http://www.ncbi.nlm.nih.gov/pubmed/2322523>.
- Schoop, U., Kluger, W., Dervisbegovic, S., Goharkhay, K., Wernisch, J., Georgopoulos, A., Sperr, W. & Moritz, A. (2006). Innovative wavelengths in endodontic treatment. *Lasers in surgery and medicine*. [Online]. 38 (6). p.pp. 624–30. Available from: <http://www.ncbi.nlm.nih.gov/pubmed/16685700>.
- Sedaghatfar, M., August, M.A. & Dodson, T.B. (2005). Panoramic radiographic

- findings as predictors of inferior alveolar nerve exposure following third molar extraction. *Journal of oral and maxillofacial surgery : official journal of the American Association of Oral and Maxillofacial Surgeons*. [Online]. 63 (1). p.pp. 3–7. Available from: <http://www.ncbi.nlm.nih.gov/pubmed/15635549>.
- Sencimen, M., Ortakoglu, K., Aydin, C., Aydintug, Y.S., Ozyigit, A., Ozen, T. & Gunaydin, Y. (2010). Is endodontic treatment necessary during coronectomy procedure? *Journal of oral and maxillofacial surgery : official journal of the American Association of Oral and Maxillofacial Surgeons*. [Online]. 68 (10). p.pp. 2385–90. Available from: <http://www.ncbi.nlm.nih.gov/pubmed/20663600>.
- Sisk, A.L., Hammer, W.B., Shelton, D.W. & Joy, E.D. (1986). Complications following removal of impacted third molars: The role of the experience of the surgeon. *Journal of Oral and Maxillofacial Surgery*. 44 (11). p.pp. 855–859.
- Smith, A.C., Barry, S.E., Allan Chiong, Bds.Y., Despina Hadzakis, Bds., Sung-Lac Kha, Bds., Steven Mok, Bds.C. & Daniel Sable, Bds.L. (1997). Inferior alveolar nerve damage following removal of mandibular third molar teeth. A prospective study using panoramic radiography. *Australian Dental Journal*. 42 (3). p.pp. 149–52.
- Susarla, S.M. & Dodson, T.B. (2007). Preoperative computed tomography imaging in the management of impacted mandibular third molars. *Journal of oral and maxillofacial surgery : official journal of the American Association of Oral and Maxillofacial Surgeons*. [Online]. 65 (1). p.pp. 83–8. Available from: <http://www.ncbi.nlm.nih.gov/pubmed/17174769>.
- Tantanapornkul, W., Okouchi, K., Fujiwara, Y., Yamashiro, M., Maruoka, Y.,

- Ohbayashi, N. & Kurabayashi, T. (2007). A comparative study of cone-beam computed tomography and conventional panoramic radiography in assessing the topographic relationship between the mandibular canal and impacted third molars. *Oral surgery, oral medicine, oral pathology, oral radiology, and endodontics*. [Online]. 103 (2). p.pp. 253–9. Available from: <http://www.ncbi.nlm.nih.gov/pubmed/17234544>.
- Tay, A.B.G. & Zuniga, J.R. (2007). Clinical characteristics of trigeminal nerve injury referrals to a university centre. *International journal of oral and maxillofacial surgery*. [Online]. 36 (10). p.pp. 922–7. Available from: <http://www.ncbi.nlm.nih.gov/pubmed/17875382>.
- Tolstunov, L. (2010). Pericoronar Ostectomy as Alternative Treatment Option for Extraction of Impacted Mandibular Third Molars in Proximity to Inferior Alveolar Nerve. *Journal of Oral and Maxillofacial Surgery*. [Online]. 68 (1). p.pp. 231–232. Available from: <http://linkinghub.elsevier.com/retrieve/pii/S0278239109016280>.
- Tolstunov, L., Javid, B., Keyes, L. & Nattestad, A. (2011). Pericoronar ostectomy: an alternative surgical technique for management of mandibular third molars in close proximity to the inferior alveolar nerve. *Journal of oral and maxillofacial surgery : official journal of the American Association of Oral and Maxillofacial Surgeons*. [Online]. 69 (7). p.pp. 1858–66. Available from: <http://www.ncbi.nlm.nih.gov/pubmed/21549479>.
- Wallace, J., Byrne, C. & Clarke, M. (2014). Improving the uptake of systematic reviews: a systematic review of intervention effectiveness and relevance. *BMJ Open*. 4 (10). p.pp. 1–13.

Whitaker, D.D. & Shankie, R.J. (1974). A study of the histologic reaction of submerged root segments. *Oral surgery, oral medicine, and oral pathology*. [Online]. 37 (6). p.pp. 919–35. Available from: <http://www.ncbi.nlm.nih.gov/pubmed/4208960>.

Zuniga, J.R. (2009). Management of third molar-related nerve injuries: observe or treat? *The Alpha omegan*. [Online]. 102 (2). p.pp. 79–84. Available from: <http://www.ncbi.nlm.nih.gov/pubmed/19591333>.

End of the Sample Work



See other sample in www.pubrica.com

[Contact Us](#)